TRAUMATISMES DU RACHIS CERVICAL INFERIEUR CLASSIFICATIONS

M D. 38 ans, amené par le SAMU

Chute en VTT tête en avant à 16H
ACR initial récupéré
Tétraplégie + priapisme
IOT puis transfert réanimation
Stable sans amine

Appel neurochirurgien de garde.

Quelle est votre prise en charge?

A) Appel du sénior
B) IRM médullaire en urgence
C) Scanner cervical en urgence
D) Body-scanner
E) Radiographies du rachis

Un scanner est réalisé :

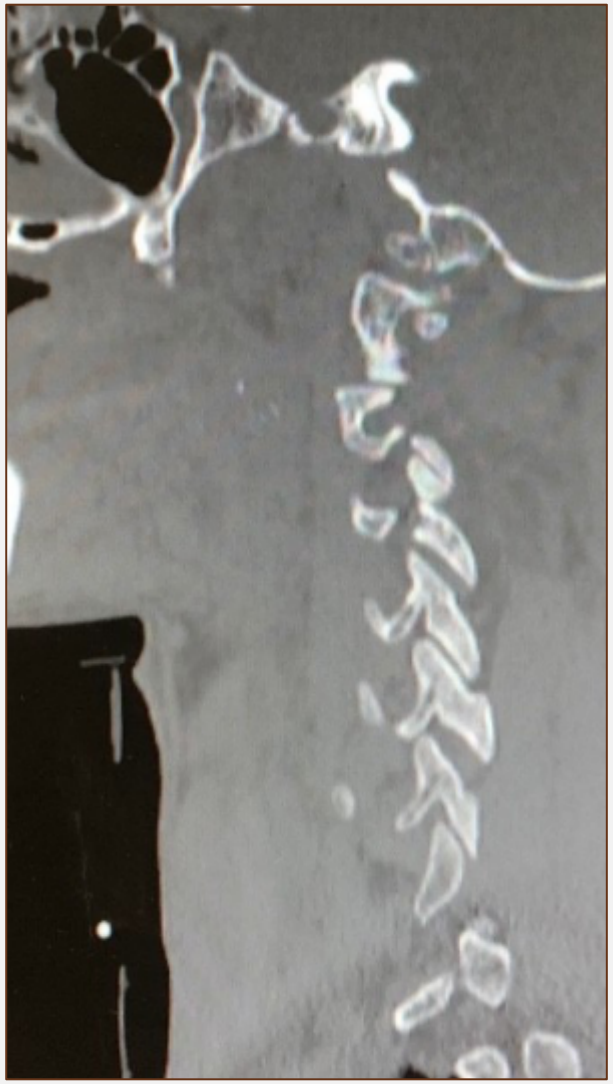

A) Il s'agit d'une lésion instable de type A3 de la classification d'Argenson. Réduction et fixation au bloc opératoire en urgence.

B) Il manque des éléments pour prendre une décision thérapeutique

C) Les classification du rachis cervical peuvent nous aider à prendre une décision thérapeutique

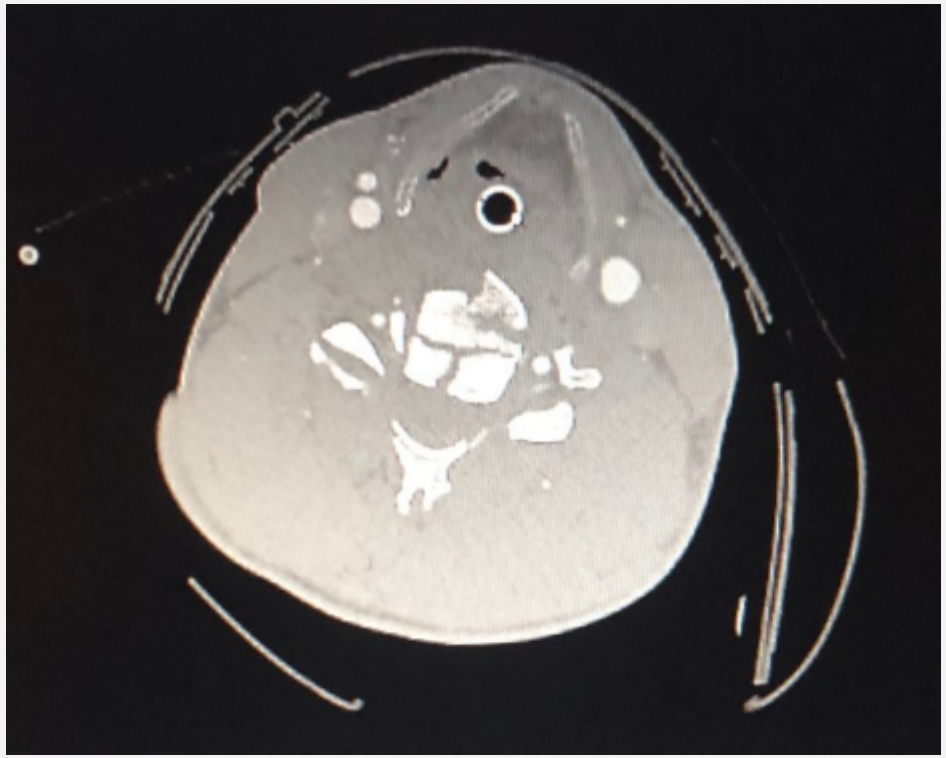

CLASSIFICATIONS DU RACHIS CERVICAL TRAUMATIQUE

Holdsworth
1970

Allen et Ferguson
1982
K : O,53

Harris
1986
K : 0,42

Argenson
1997

SLIC
2007
K : 0,71

AOspine
2016
K : 0,64

ARGENSON, 1997

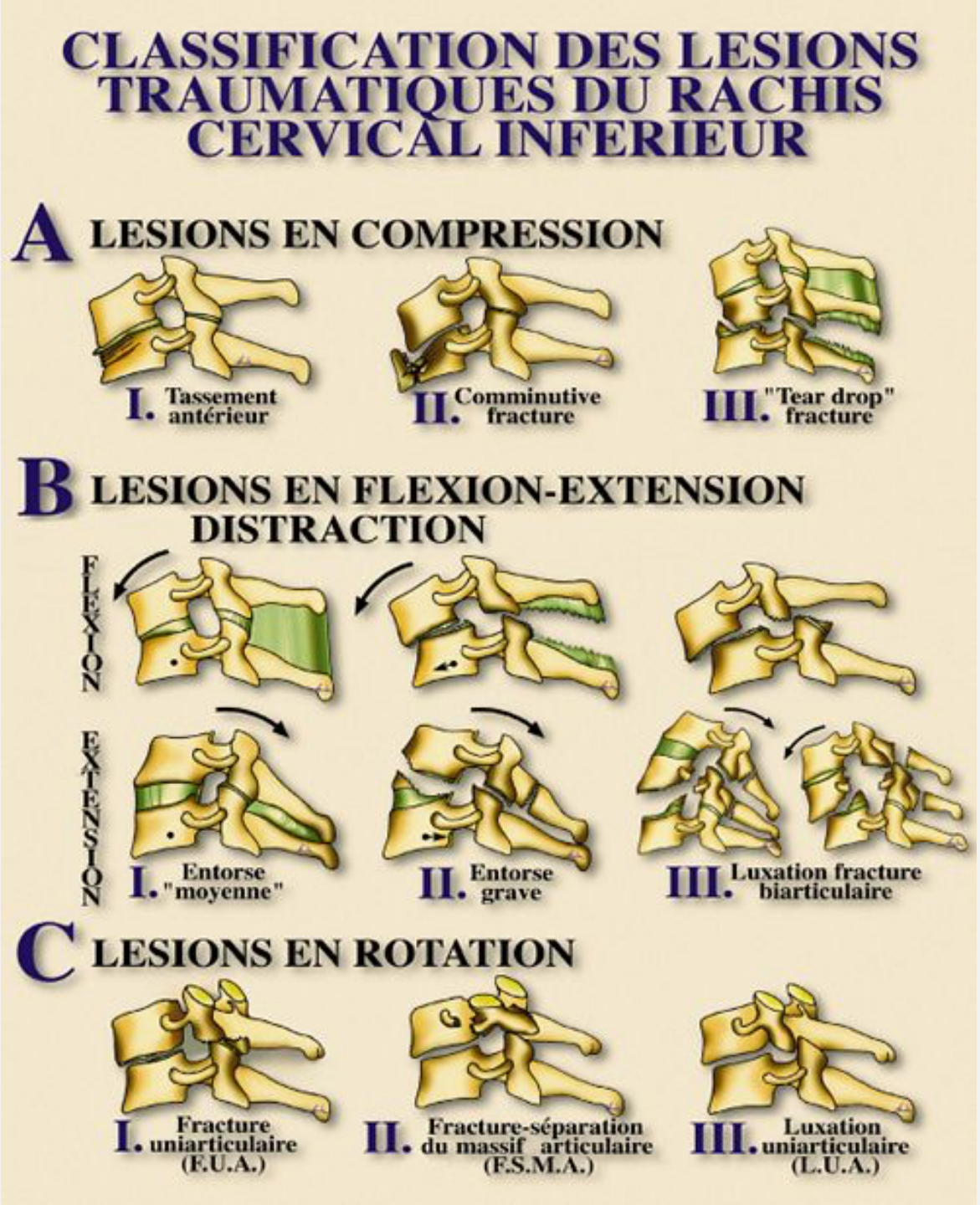

THE SUBAXIAL INJURY CLASSIFICATION SCORING SYSTEM (SLIC)

VACARRO AR ET AL, SPINE 2007

Morphology of Injury	Disco-ligamentous Integrity	Neurologic Status

< 4 : non-surgical management

= 4 : equivocal

> 4 : surgical management

The Subaxial Injury Classification Scoring System (SLIC)

Morphology of Injury

Disco-ligamentous Integrity

Neurologic Status

Compression
(1 or 2 points)

Distraction
(3 points)

Translation/rotation
(4 points)

The Subaxial Injury Classification Scoring System (SLIC)

Morphology of Injury

Disco-ligamentous Integrity

Neurologic Status

Compression

1 point

2 points si BURST

- Compression simple
- Fracture sagittale ou coronale
- Compression + BURST

The Subaxial Injury Classification Scoring System (SLIC)

Morphology of Injury

Disco-ligamentous Integrity

Neurologic Status

Compression
1 point
2 points si BURST

- **Compression simple**
- Fracture sagittale ou coronale
- Compression + BURST

The Subaxial Injury Classification Scoring System (SLIC)

Morphology of Injury

Disco-ligamentous Integrity

Neurologic Status

Compression

1 point

2 points si BURST

Compression simple

Fracture sagittale ou coronale

Compression + BURST

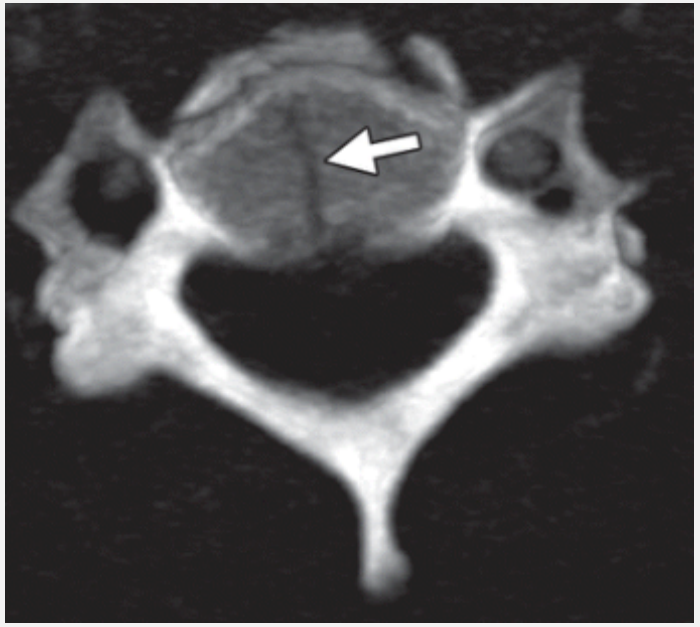

The Subaxial Injury Classification Scoring System (SLIC)

Morphology of Injury

Disco-ligamentous Integrity

Neurologic Status

Compression
1 point
2 points si BURST

- Compression simple
- Fracture sagittale ou coronale
- **Compression + BURST**

+ 1 POINT

The Subaxial Injury Classification Scoring System (SLIC)

Morphology of Injury

Disco-ligamentous Integrity

Neurologic Status

Distraction
3 points

- Hyperextension
- Hyperflexion

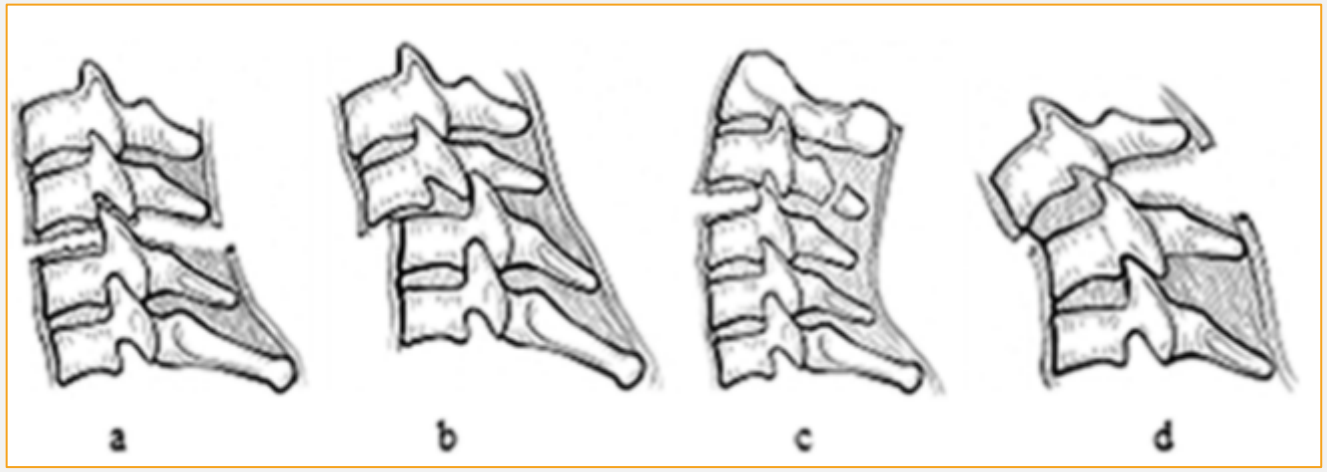

The Subaxial Injury Classification Scoring System (SLIC)

Morphology of Injury

Disco-ligamentous Integrity

Neurologic Status

Distraction
3 points

Hyperextension

Hyperflexion

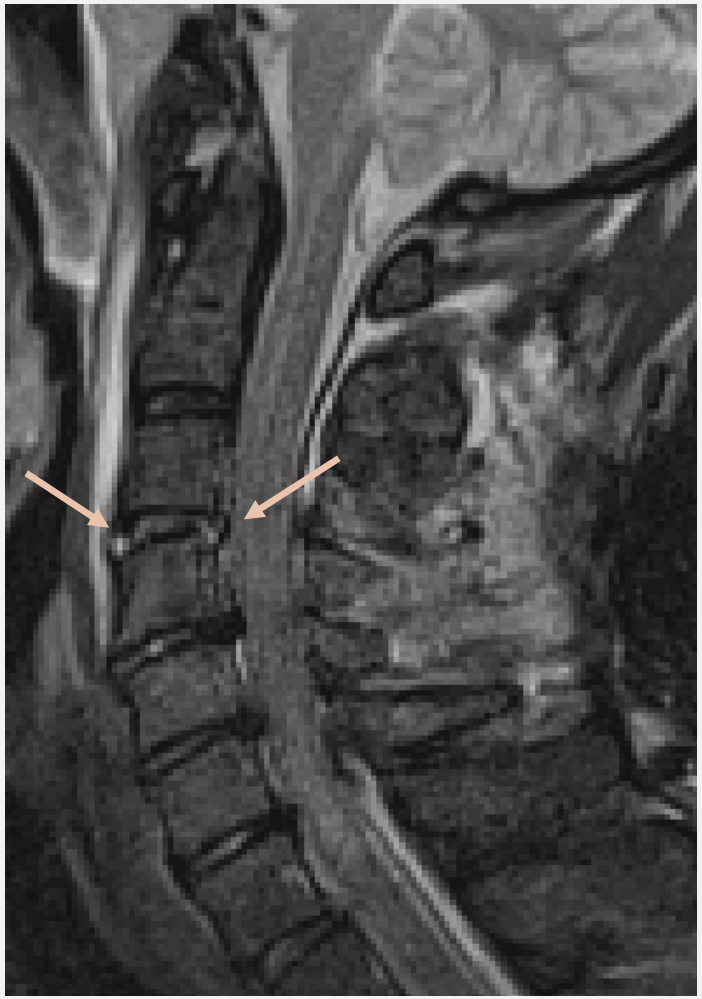

The Subaxial Injury Classification Scoring System (SLIC)

Morphology of Injury

Distraction
3 points

- Hyperextension
- **Hyperflexion**

Disco-ligamentous Integrity

Neur

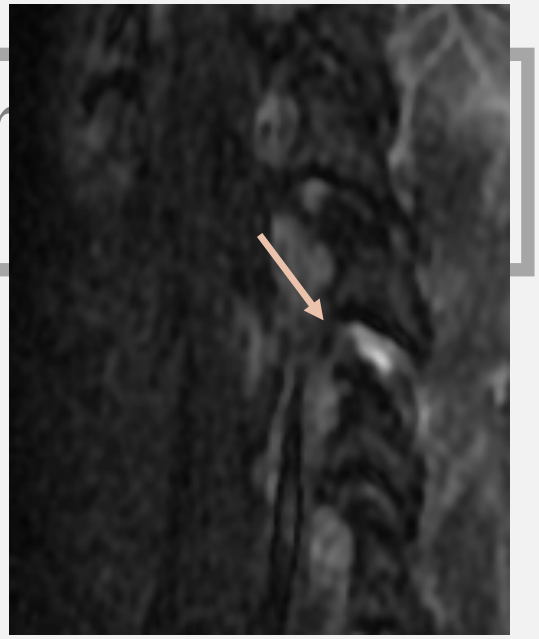

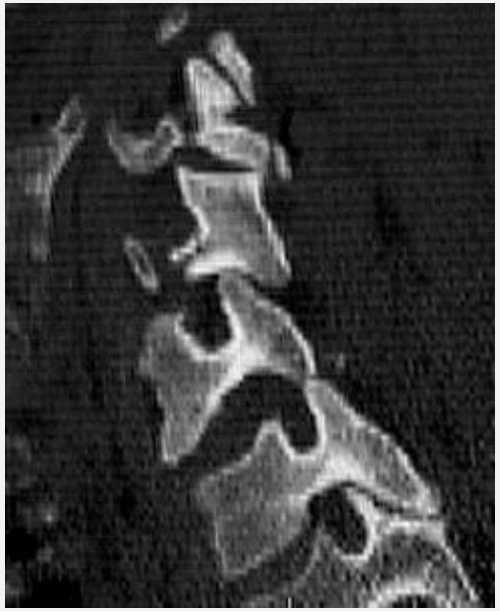

The Subaxial Injury Classification Scoring System (SLIC)

Morphology of Injury

Disco-ligamentous Integrity

Neurologic Status

Translation / Rotation
4 points

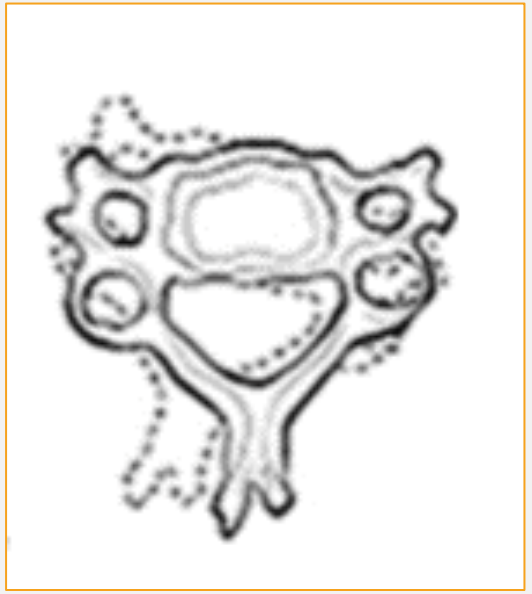

The Subaxial Injury Classification Scoring System (SLIC)

Morphology of Injury

Disco-ligamentous Integrity

Neurologic Status

Translation
Rotation
4 points

- **Fracture luxation articulaire unilatérale ou bilatérale**
- Fracture séparation de la masse latérale
- Fracture pédiculaire bilatérale

The Subaxial Injury Classification Scoring System (SLIC)

Morphology of Injury

Disco-ligamentous Integrity

Ne

Translation
Rotation
4 points

- Fracture luxation articulaire unilatérale ou bilatérale
- **Fracture séparation de la masse latérale**
- Fracture pédiculaire bilatérale

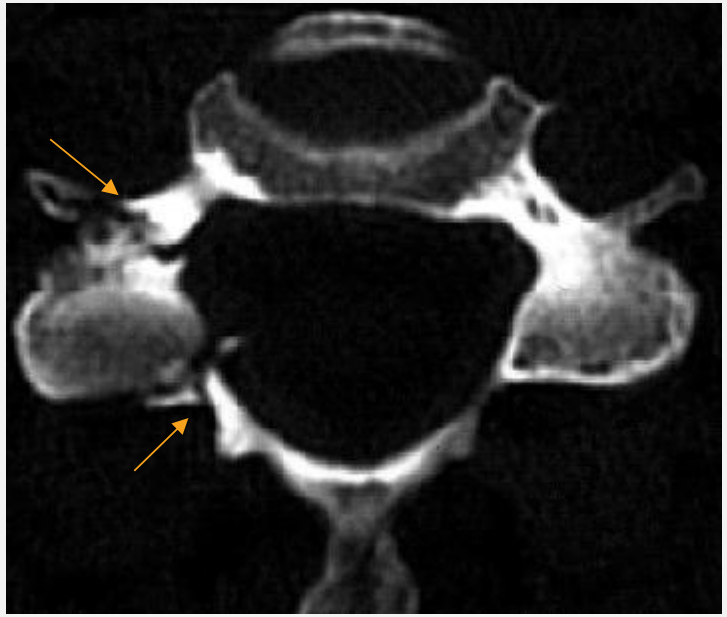

The Subaxial Injury Classification Scoring System (SLIC)

Morphology of Injury

Disco-ligamentous Integrity

Neurol

Translation
Rotation
4 points

- Fracture luxation articulaire unilatérale ou bilatérale
- Fracture séparation de la masse latérale
- **Fracture pédiculaire bilatérale**

The Subaxial Injury Classification Scoring System (SLIC)

Morphology of Injury

Disco-ligamentous Integrity

Neurologic Status

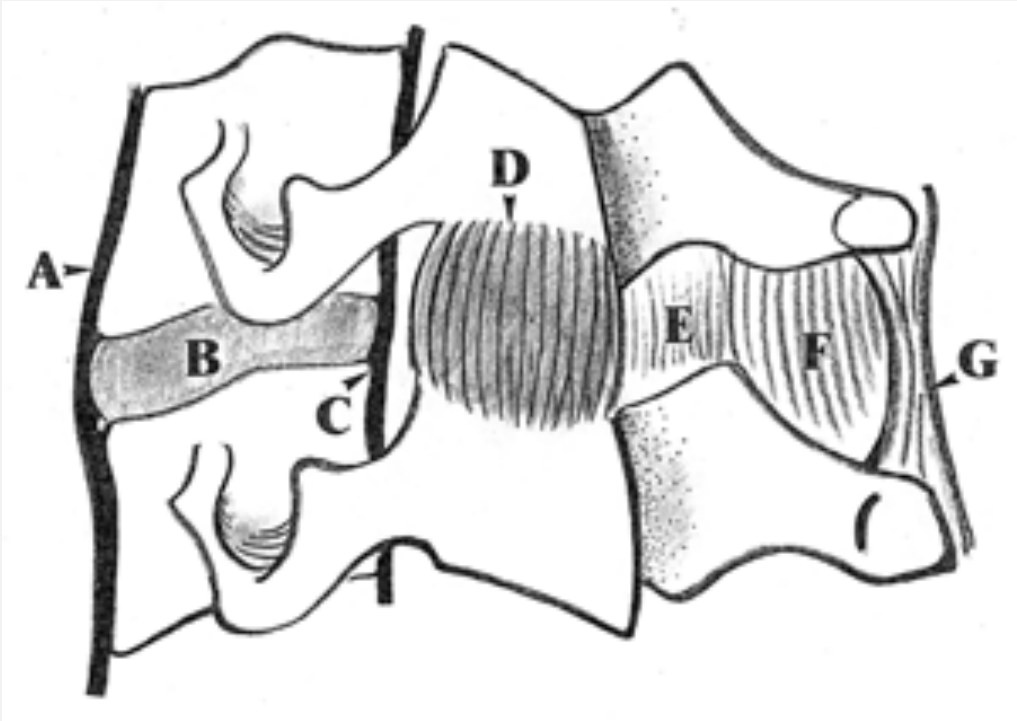

Atteinte certaine = 2 POINTS

- LLA/ disque
- Capsule articulaire
- Ligament inter-épineux

Atteinte indéterminée = 1 POINT

Signes indirects = Radiographies, TDM

Signes directs = **HYPERSIGNAL T2**

The Subaxial Injury Classification Scoring System (SLIC)

Morphology of Injury

Disco-ligamentous Integrity

Neurologic Status

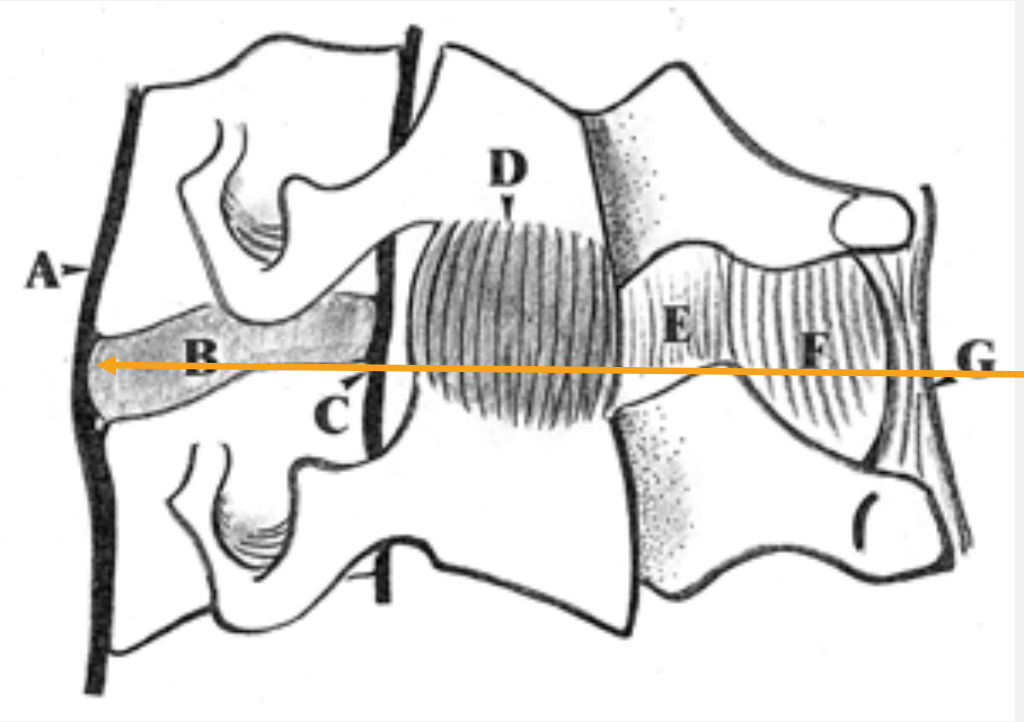

- LLA
Baillement discal

2 POINTS

The Subaxial Injury Classification Scoring System (SLIC)

Morphology of Injury

Disco-ligamentous Integrity

Neurologic Status

➢ Capsule articulaire

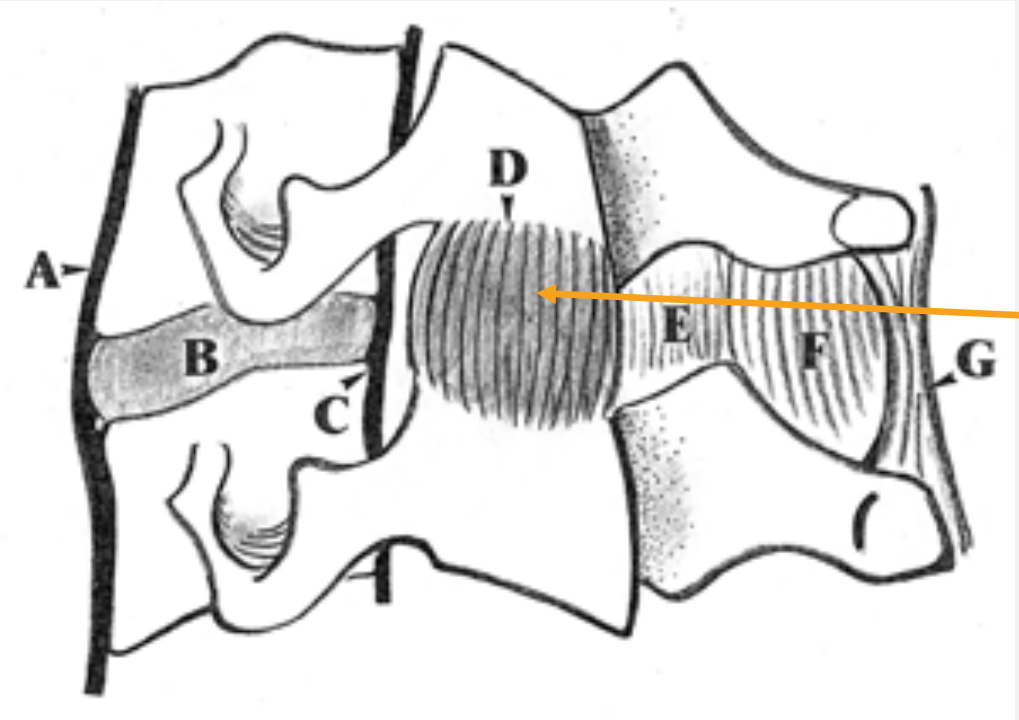

Diastasis > 2mm, Découvrement articulaire > 50%

2 POINTS

The Subaxial Injury Classification Scoring System (SLIC)

Morphology of Injury

Disco-ligamentous Integrity

Neurologic Status

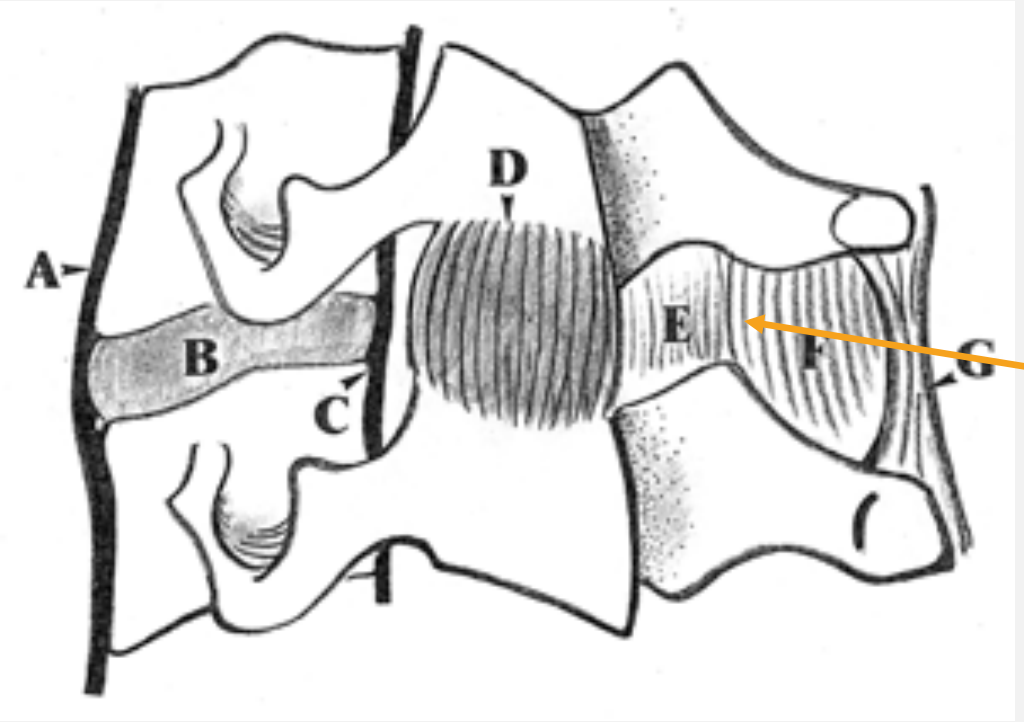

➢ Ligament inter-épineux

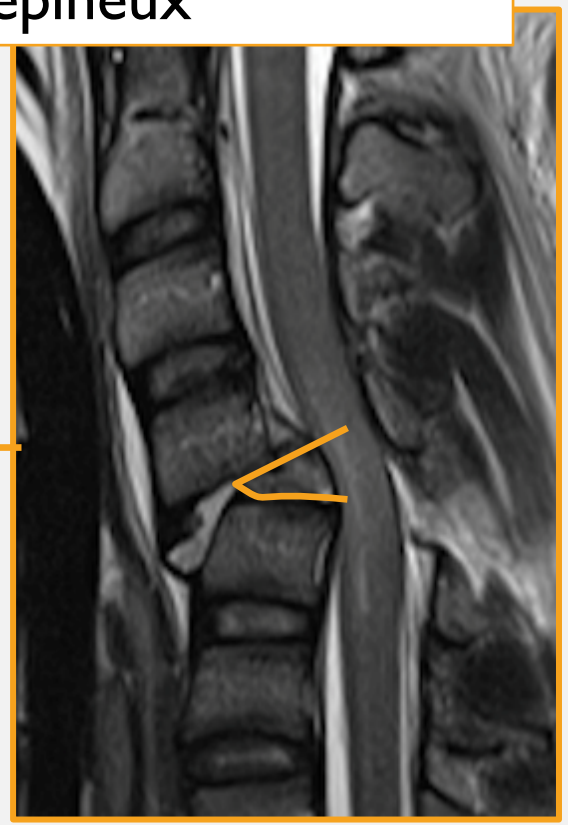

Angulation > 11°

The Subaxial Injury Classification Scoring System (SLIC)

Morphology of Injury

Disco-ligamentous Integrity

Neurologic Status

Atteinte indéterminée
= 1 POINT

- Hypersignal T2 isolé
- Ecartement de l'espace interépineux isolé

Atteinte certaine
= 2 POINT

- Articulaires perchées
- Luxation articulaire
- Baillement discal

The Subaxial Injury Classification Scoring System (SLIC)

Morphology of Injury

Disco-ligamentous Integrity

Neurologic Status

Neurologic Status	**SLIC Score***
Intact	0
Root injury	1
Complete level *(ASIA A)*	2
Incomplete level *(ASIA B, C, D)*	3

+1 si compression cordon médullaire

SCORE FINAL

< 4	*non-surgical management*
= 4	*?*
> 4	*surgical management*

Kappa inter-observateur : 0,71

AOSPINE SUBAXIAL CERVICAL SPINE INJURY CLASSIFICATION SYSTEM

VACARO ET AL, EUR SPINE J 2016

- Morphologie
- Atteinte articulaire
- Atteinte neurologique
- Modérateurs spécifiques

Aospine Subaxial Cervical Spine Injury Classification System

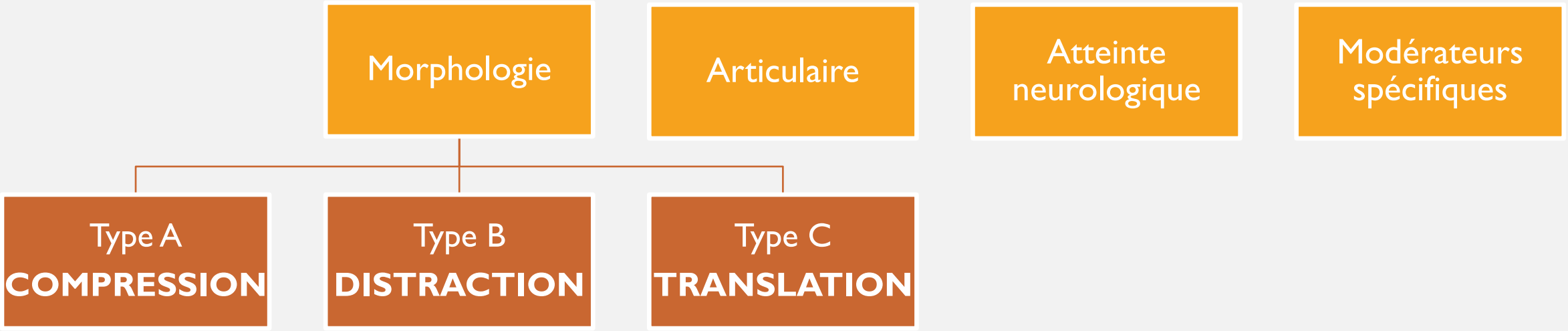

Aospine Subaxial Cervical Spine Injury Classification System

- Morphologie
  - Type A **COMPRESSION**
    - A0
  - Type B **DISTRACTION**
  - Type C **TRANSLATION**
- Articulaire
- Atteinte neurologique
- Modérateurs spécifiques

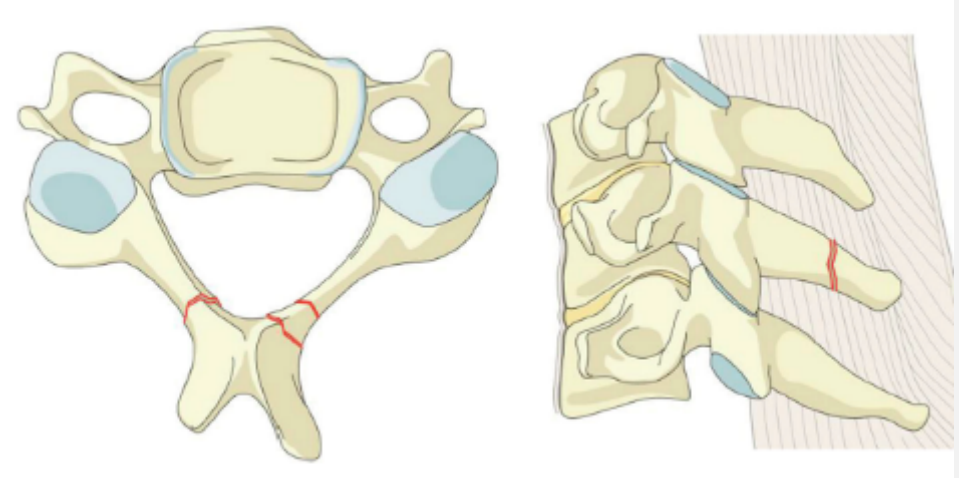

Aospine Subaxial Cervical Spine Injury Classification System

Morphologie

Articulaire

Atteinte neurologique

Modérateurs spécifiques

Type A
COMPRESSION

Type B
DISTRACTION

Type C
TRANSLATION

A0

A1

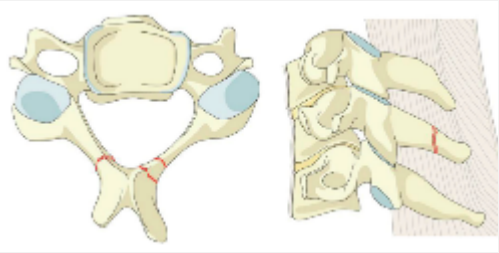

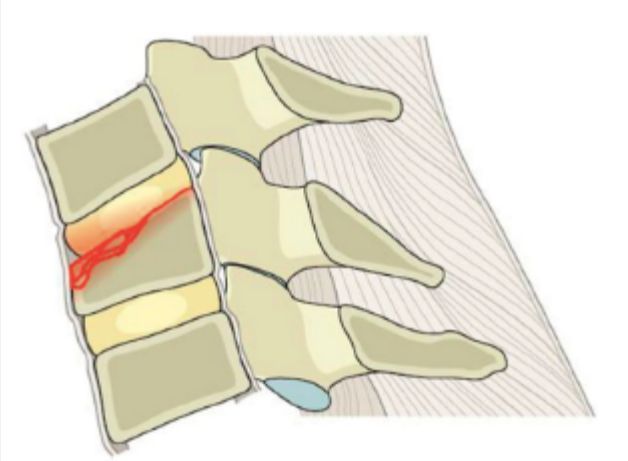

Aospine Subaxial Cervical Spine Injury Classification System

Morphologie

Articulaire

Atteinte neurologique

Modérateurs spécifiques

Type A
COMPRESSION

Type B
DISTRACTION

Type C
TRANSLATION

A0

A1

A2

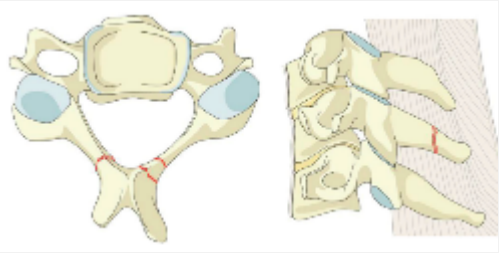

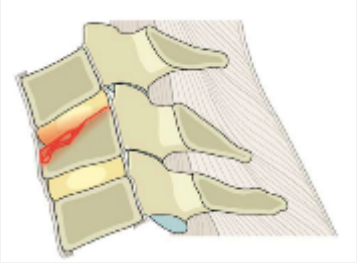

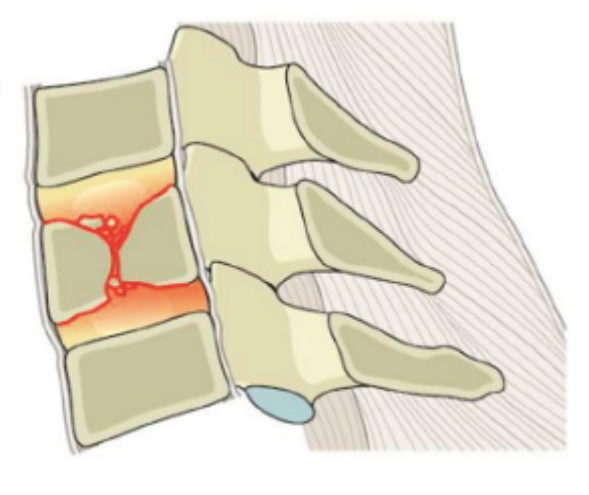

Aospine Subaxial Cervical Spine Injury Classification System

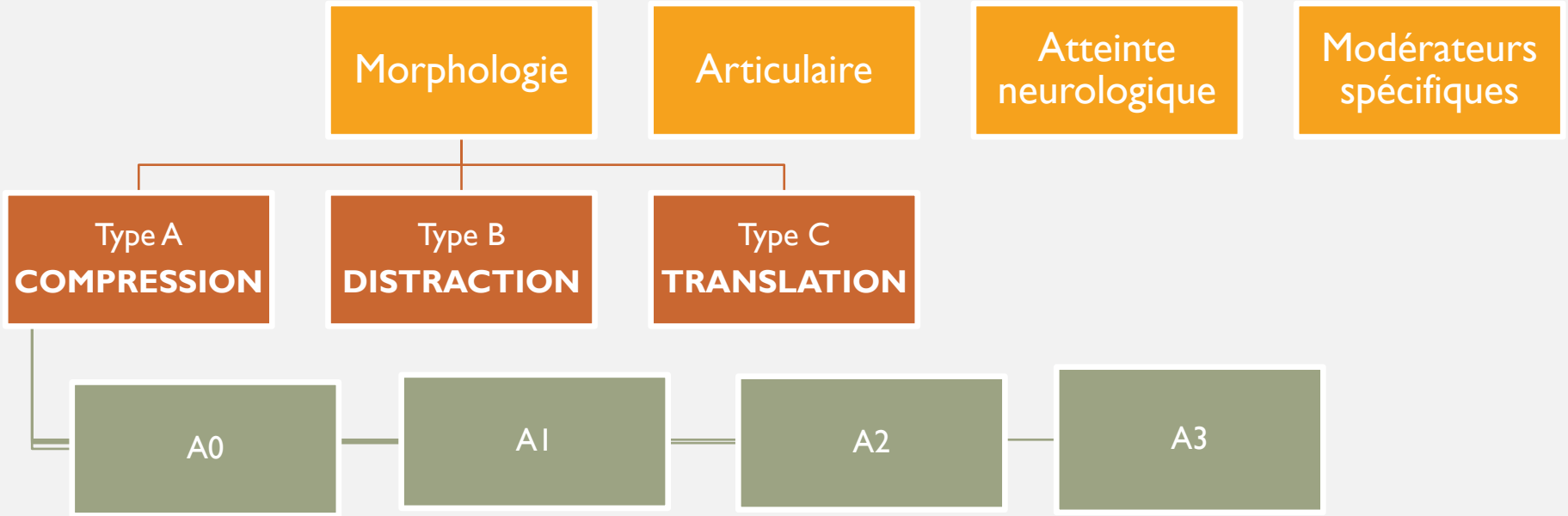

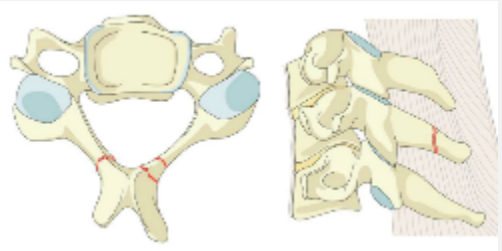

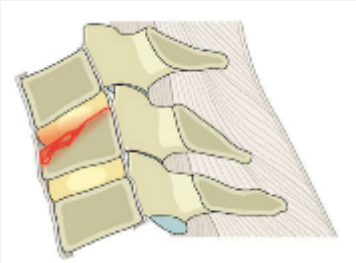

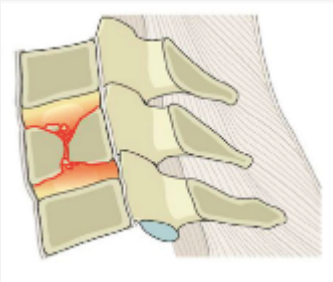

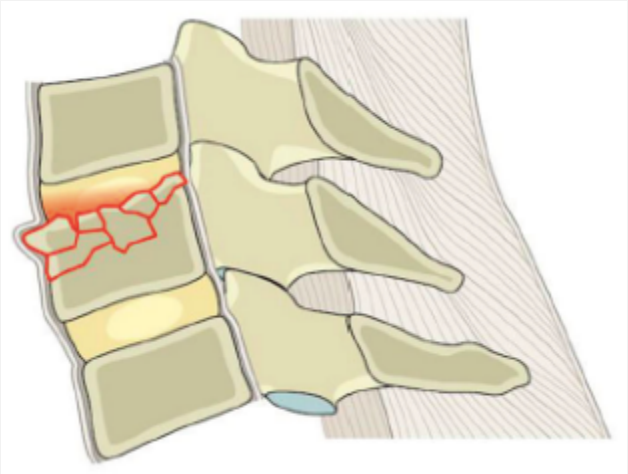

Aospine Subaxial Cervical Spine Injury Classification System

Morphologie

Articulaire

Atteinte neurologique

Modérateurs spécifiques

Type A
COMPRESSION

Type B
DISTRACTION

Type C
TRANSLATION

A0 — A1 — A2 — A3 — A4

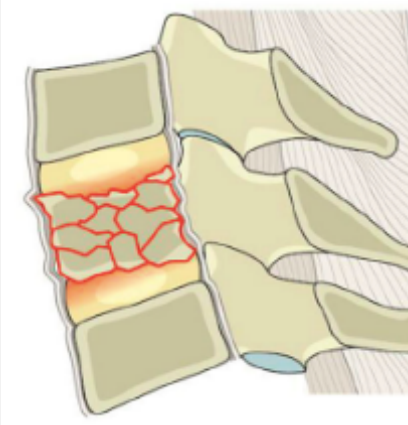

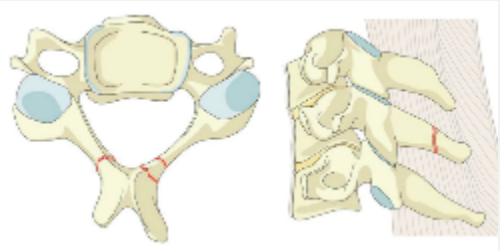

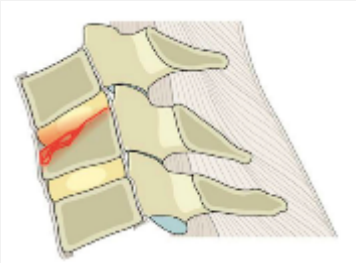

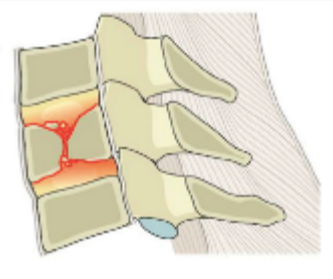

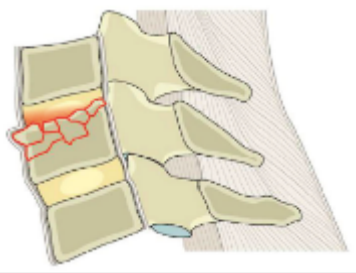

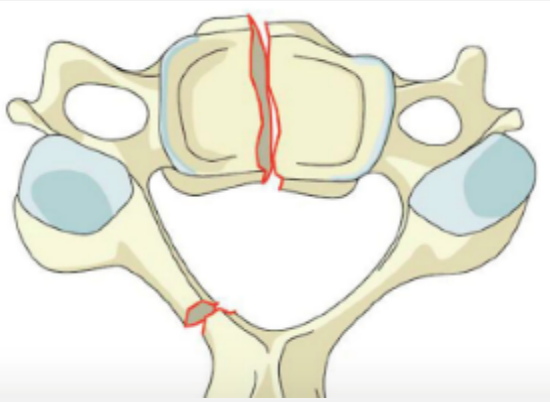

Aospine Subaxial Cervical Spine Injury Classification System

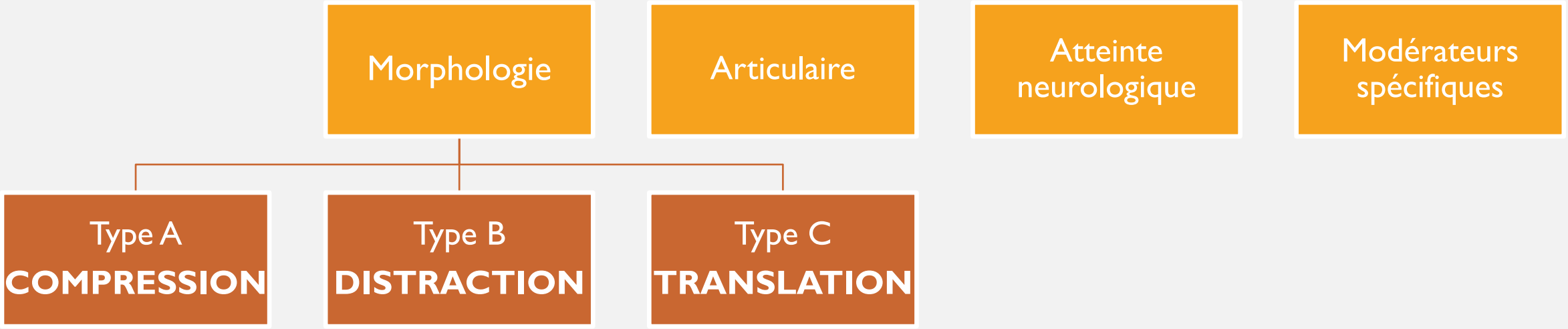

Aospine Subaxial Cervical Spine Injury Classification System

Morphologie

Articulaire

Atteinte neurologique

Modérateurs spécifiques

Type A
COMPRESSION

Type B
DISTRACTION

Type C
TRANSLATION

B1

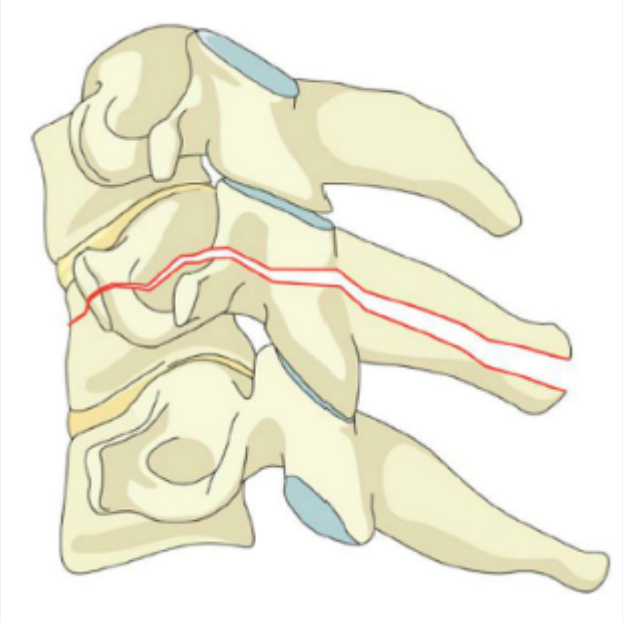

Aospine Subaxial Cervical Spine Injury Classification System

Morphologie

Articulaire

Atteinte neurologique

Modérateurs spécifiques

Type A
COMPRESSION

Type B
DISTRACTION

Ty
TRANS

B1

B2

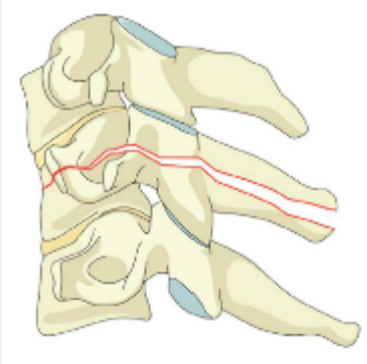

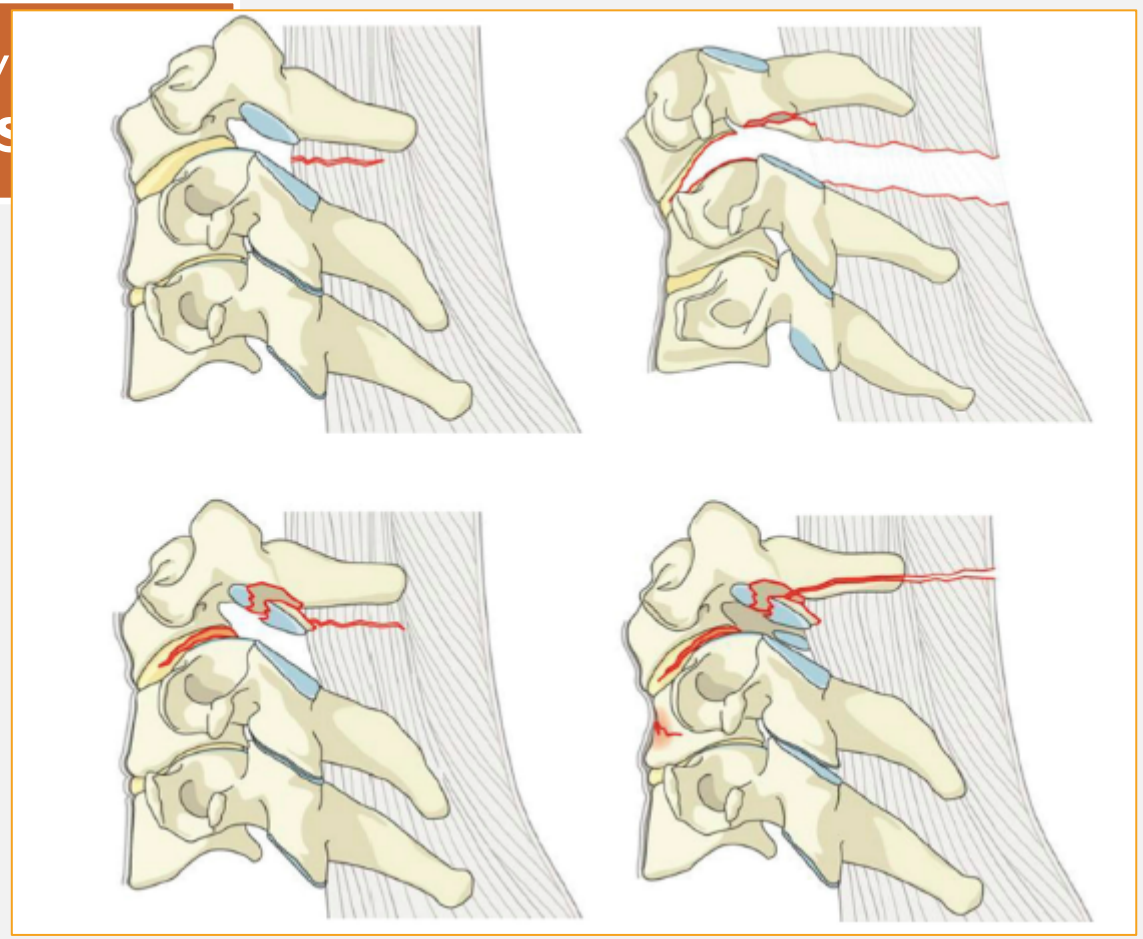

Aospine Subaxial Cervical Spine Injury Classification System

Morphologie

Articulaire

Atteinte neurologique

Modérateurs spécifiques

Type A
COMPRESSION

Type B
DISTRACTION

Type C
TRANSLATION

B1

B2

B3

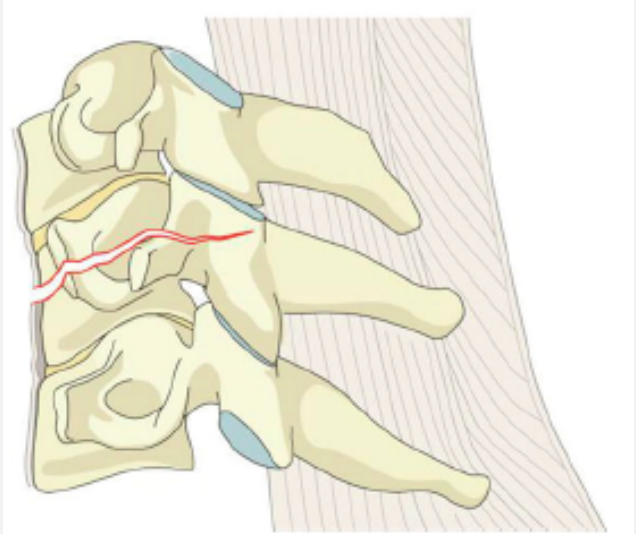

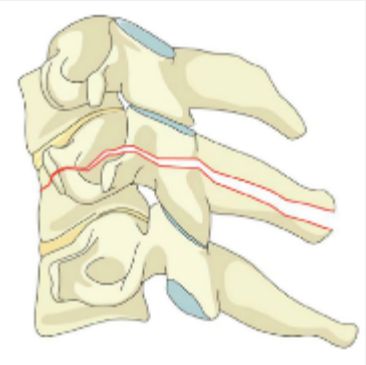

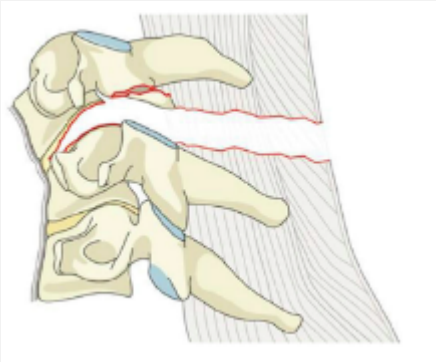

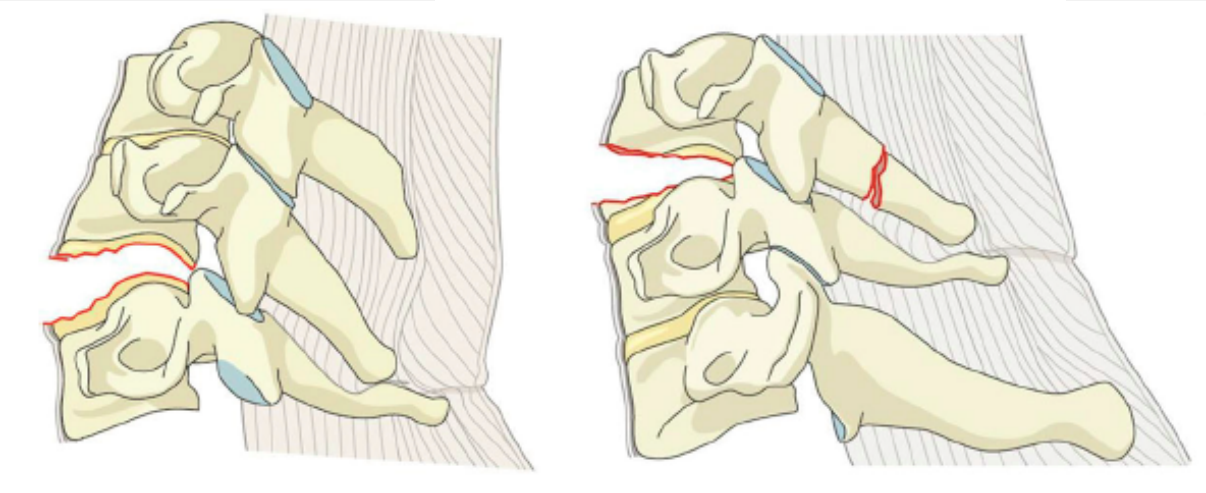

Aospine Subaxial Cervical Spine Injury Classification System

Morphologie

Articulaire

Atteinte neurologique

Modérateurs spécifiques

Type A
COMPRESSION

Type B
DISTRACTION

Type C
TRANSLATION

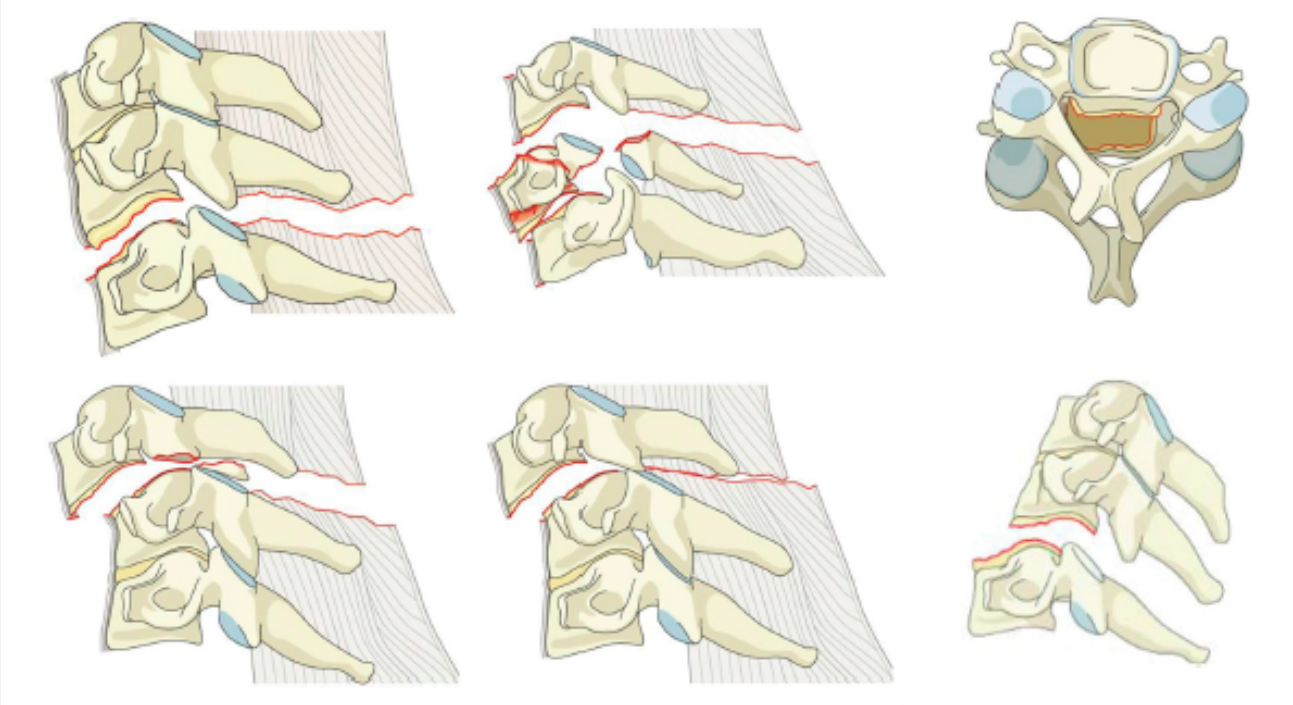

Aospine Subaxial Cervical Spine Injury Classification System

Morphologie

Articulaire

Atteinte neurologique

Modérateurs spécifiques

Aospine Subaxial Cervical Spine Injury Classification System

Morphologie

Articulaire

Atteinte neurologique

Modérateurs spécifiques

F I

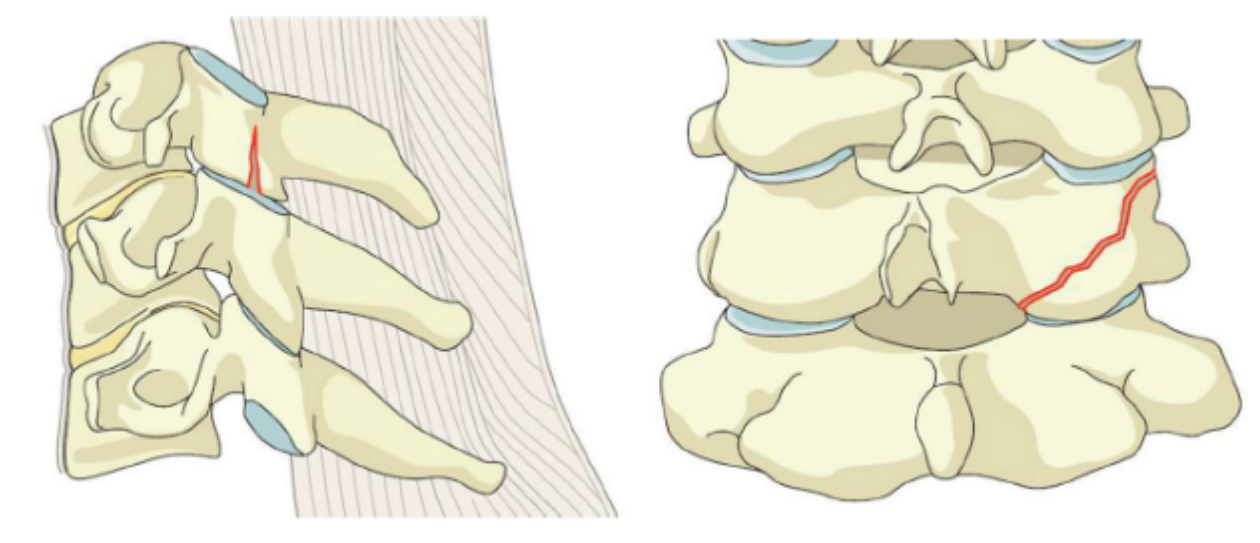

Aospine Subaxial Cervical Spine Injury Classification System

Morphologie

Articulaire

- F1
- F2

Atteinte neurologique

Modérateurs spécifiques

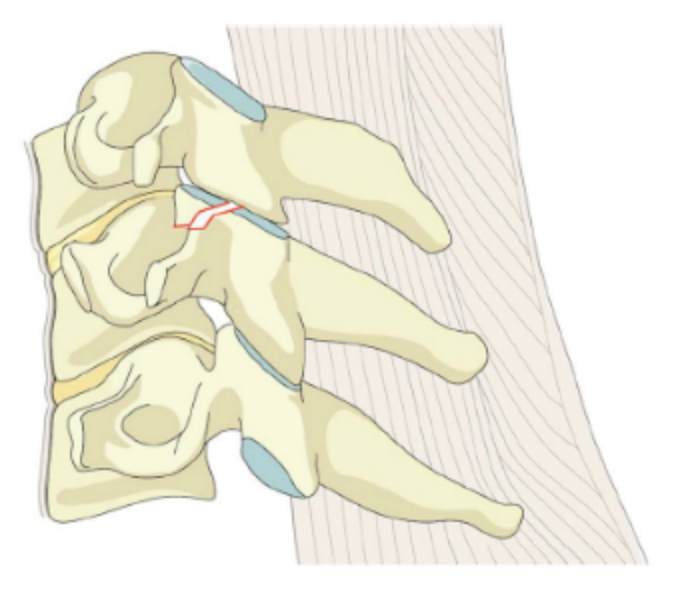

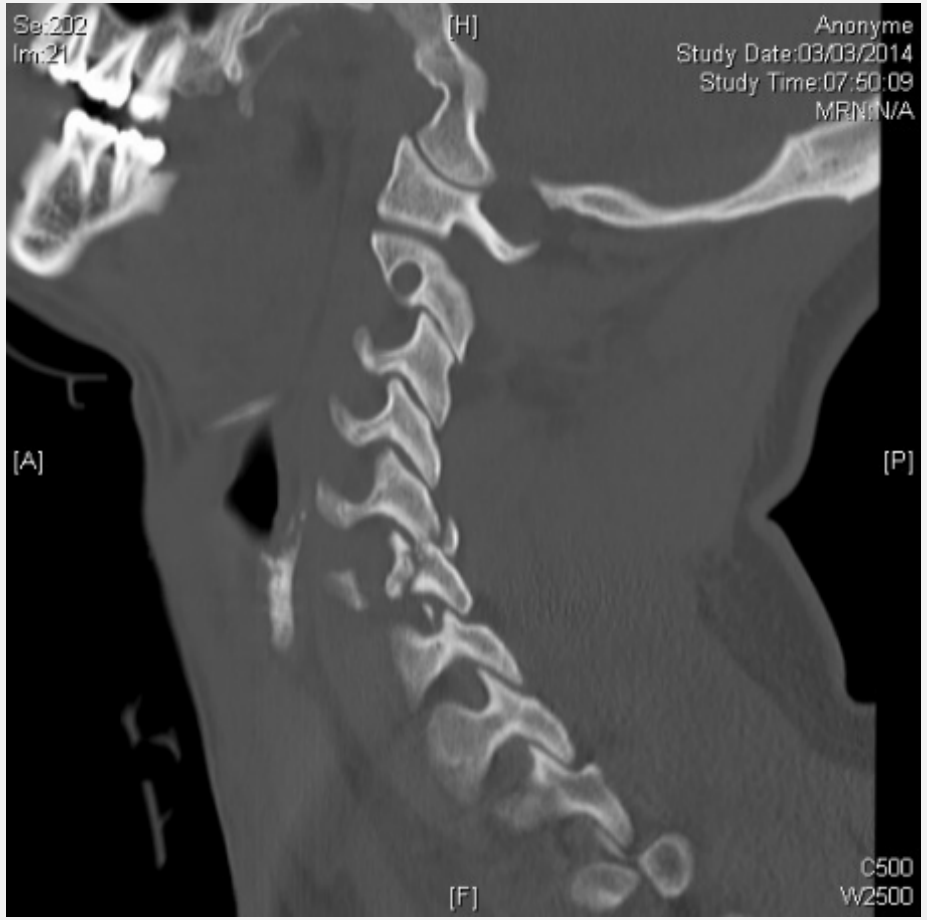

Aospine Subaxial Cervical Spine Injury Classification System

- Morphologie
- Articulaire
  - F1
  - F2
  - F3
- Atteinte neurologique
- Modérateurs spécifiques

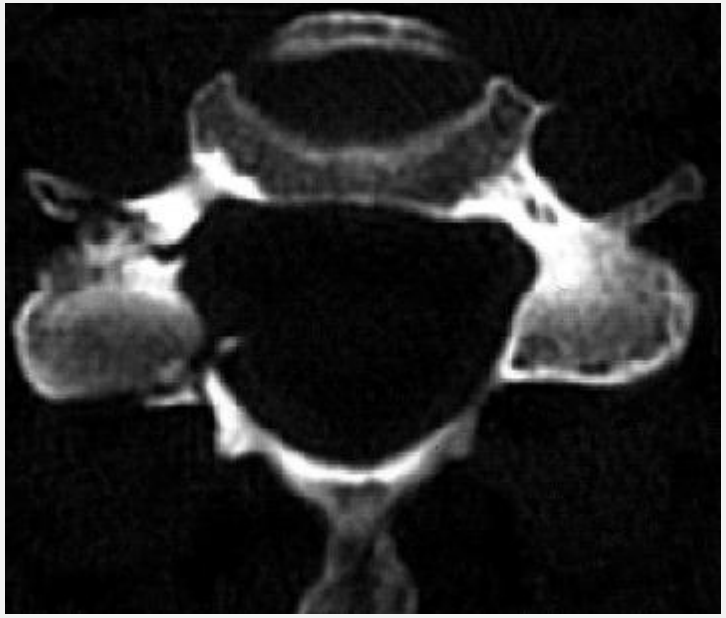

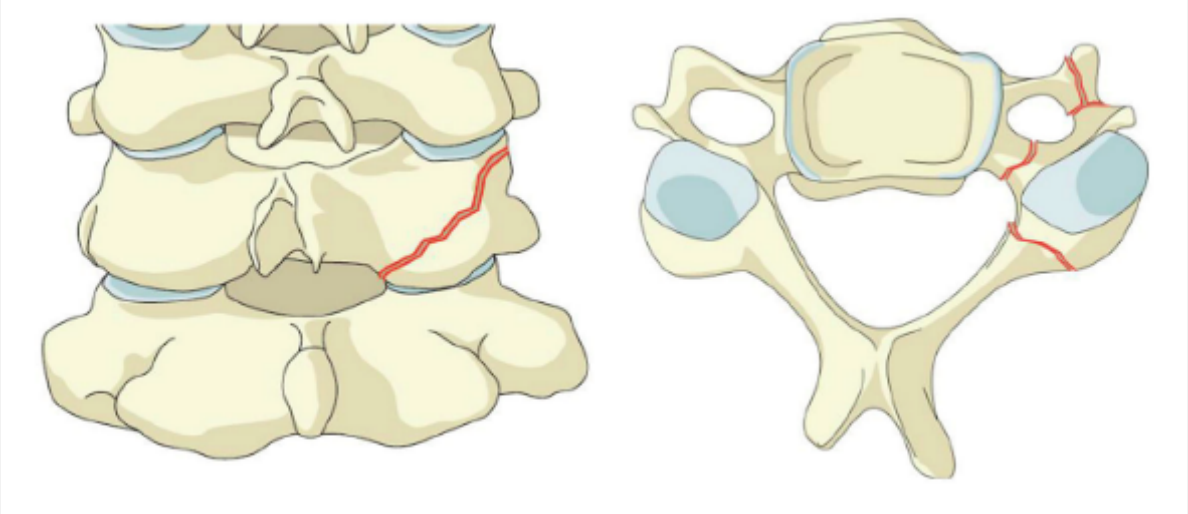

Aospine Subaxial Cervical Spine Injury Classification System

Morphologie

Articulaire

Atteinte neurologique

Modérateurs spécifiques

F1

F2

F3

F4

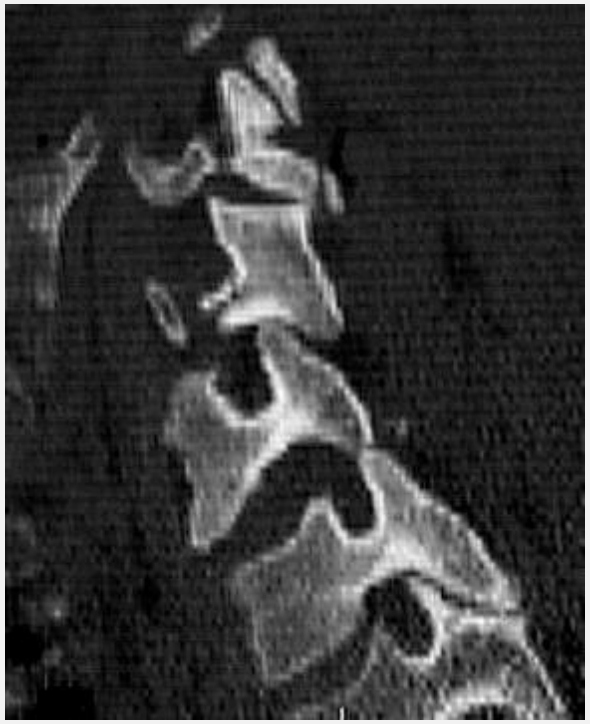

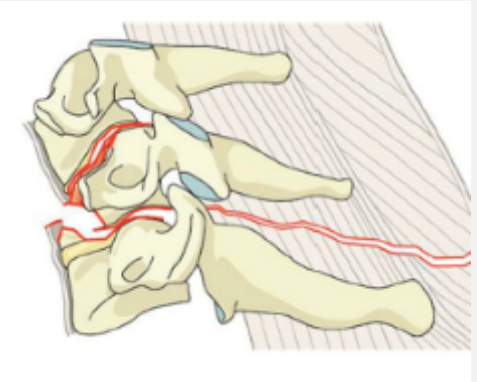

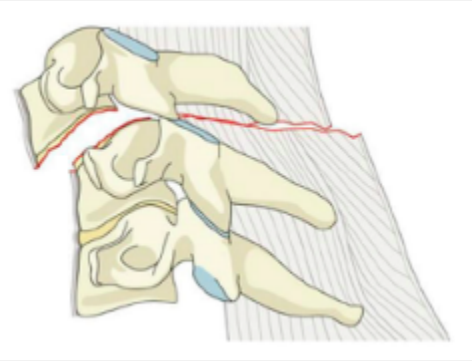

Aospine Subaxial Cervical Spine Injury Classification System

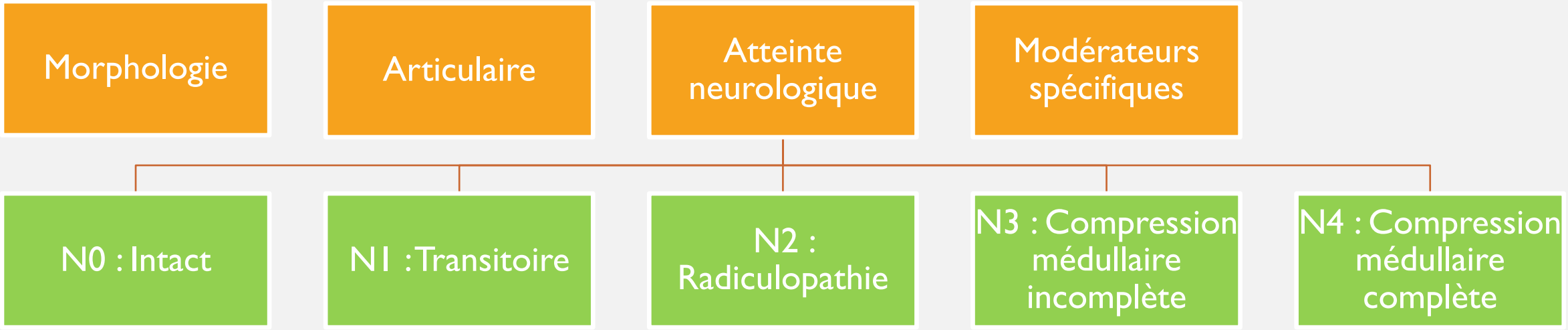

Aospine Subaxial Cervical Spine Injury Classification System

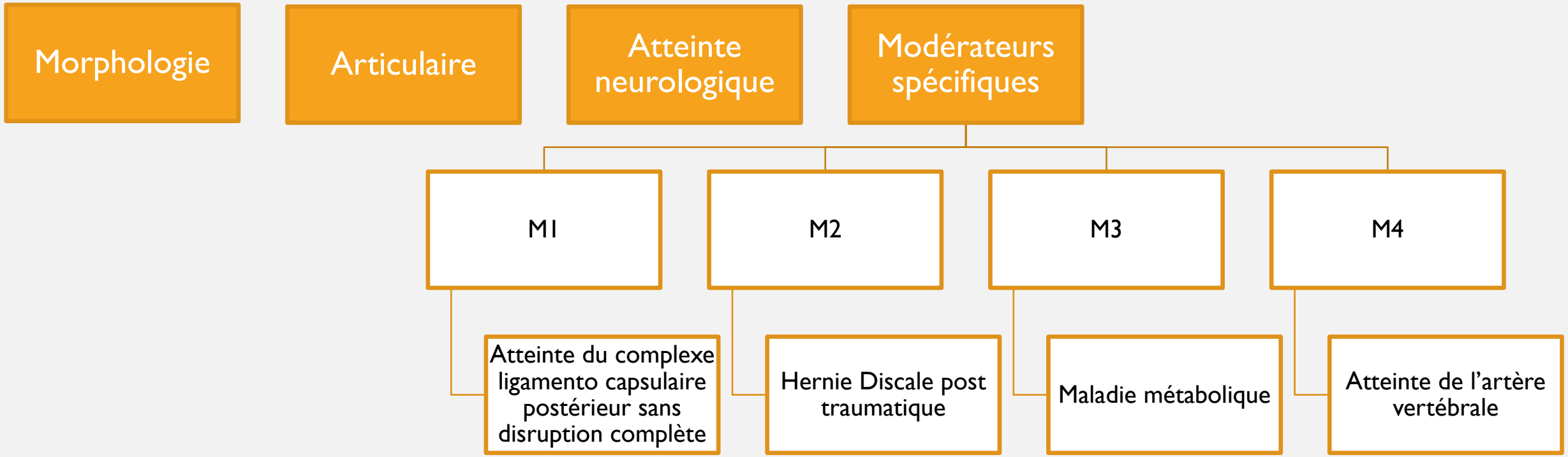

Aospine Subaxial Cervical Spine Injury Classification System

Table 1 Frequency of responses of injury types

Cervical classification	*N*	%
A0	15	2.5
A1	34	5.7
A2	28	4.7
A3	7	1.2
A4	71	11.8
B1	1	0.2
B2	77	12.8
B3	82	13.7
C	218	36.3
F1	6	1.0
F2	30	5.0
F3	24	4.0
F4	7	1.2

Kappa inter-observateur =0,64

EXEMPLE N°1

- Mme R 80 ans, piéton renversée par VL
- Plaie frontale, cervicalgie, dysesthésies 2 mains
- Allodynie, sydrome tétra-pyramidal
- Pas de déficit moteur

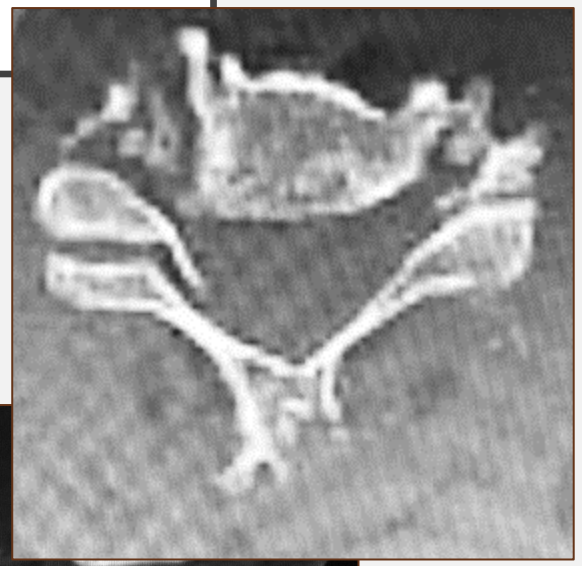

CLASSIFICATION DES LESIONS

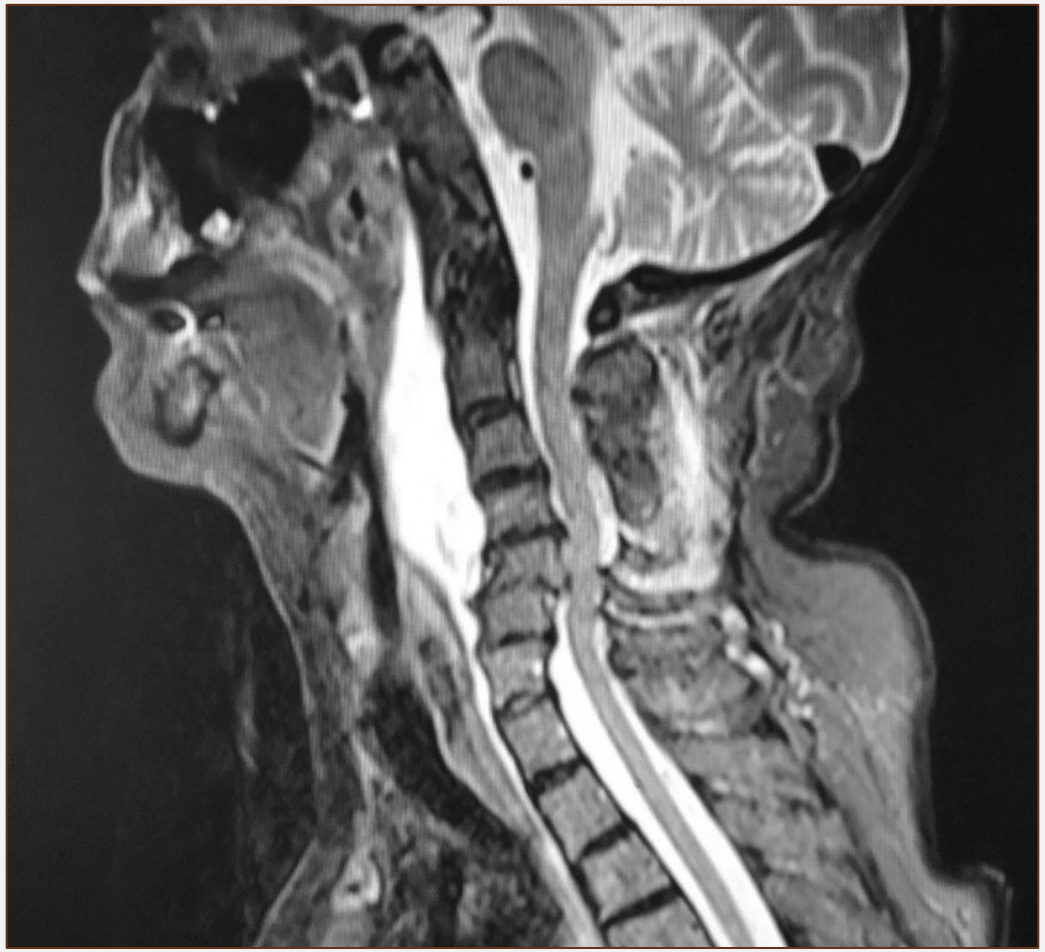

Table 1. SLIC Scale

	Points
Morphology	
No abnormality	0
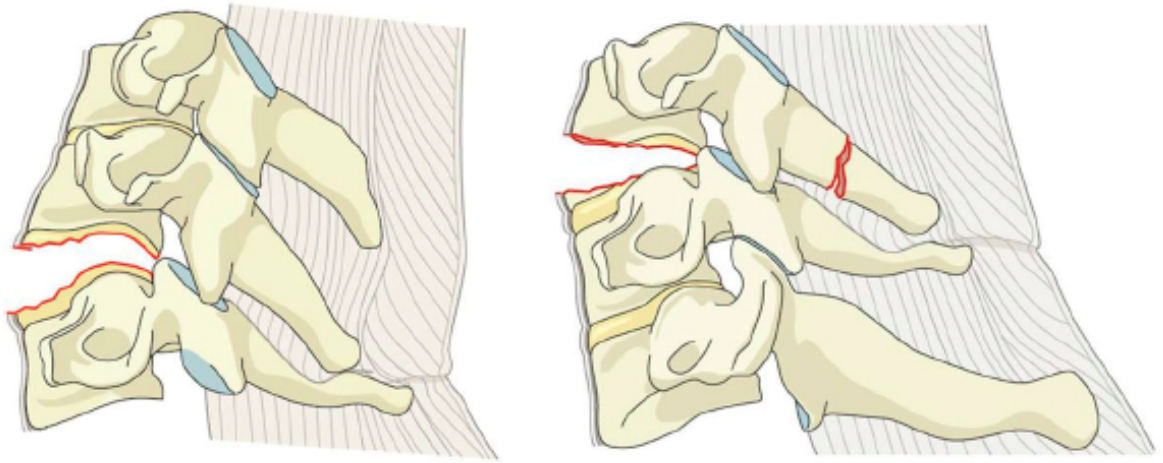	2
Disrupted (*e.g.*, widening of disc space, facet pitch or dislocation)	2
Neurological status	
Intact	0
Root injury	1
Complete cord injury	2
Incomplete cord injury	3
Continuous cord compression in setting of neuro deficit (Neuro Modifier)	+1

Aospine

Atteinte B3, N3, M1

DISTRACTION 3 points + DLC indéterminé 1 point + CM Incomplète 3 points = 7

Chirurgie en urgence

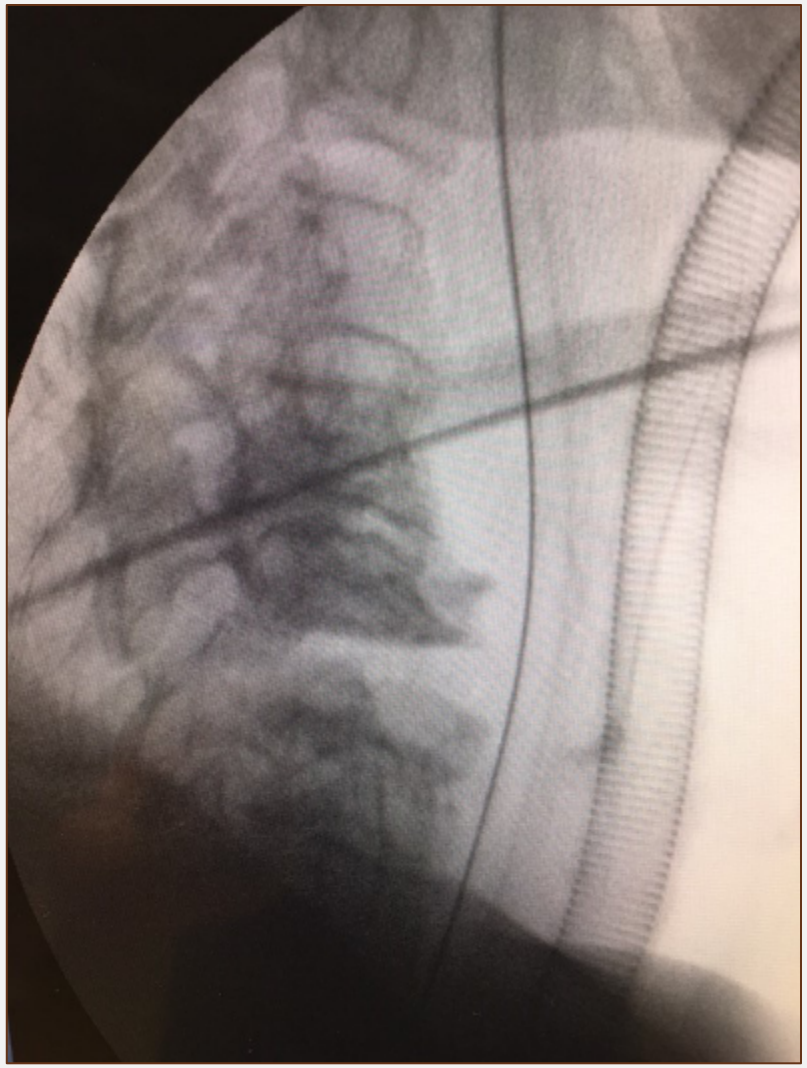

EXEMPLE N° 2

58 ans, chute de cheval.
ACR sur l'impact
Tétraplégie d'emblée.

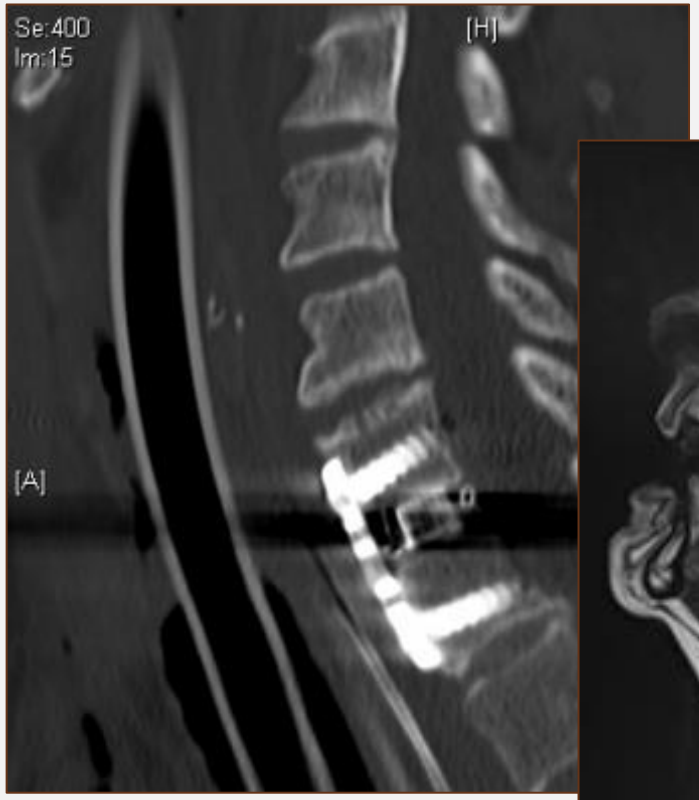

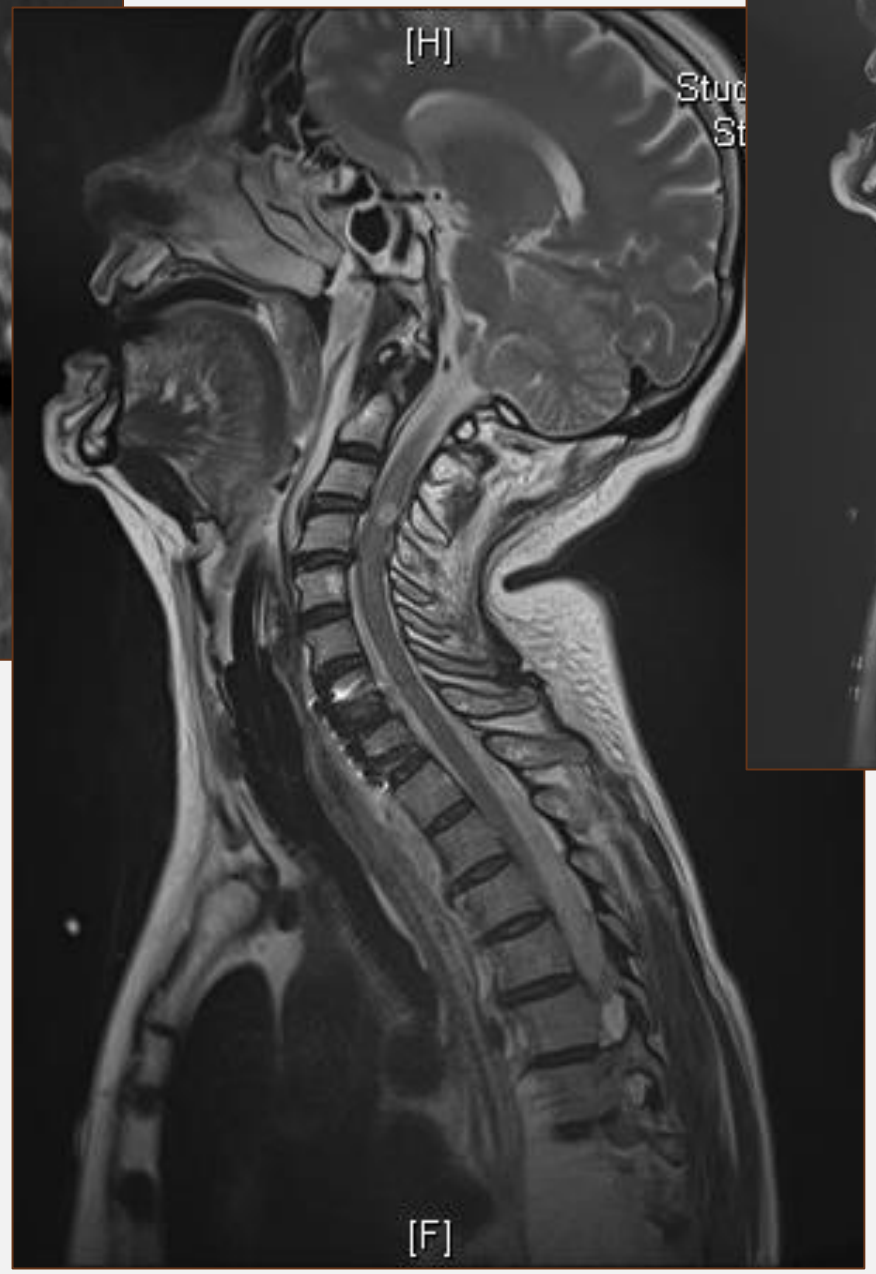

Argencon:= Type B2,
Score SLIC = 3+ 2+ 2 = 7
AOSpine : Type B3

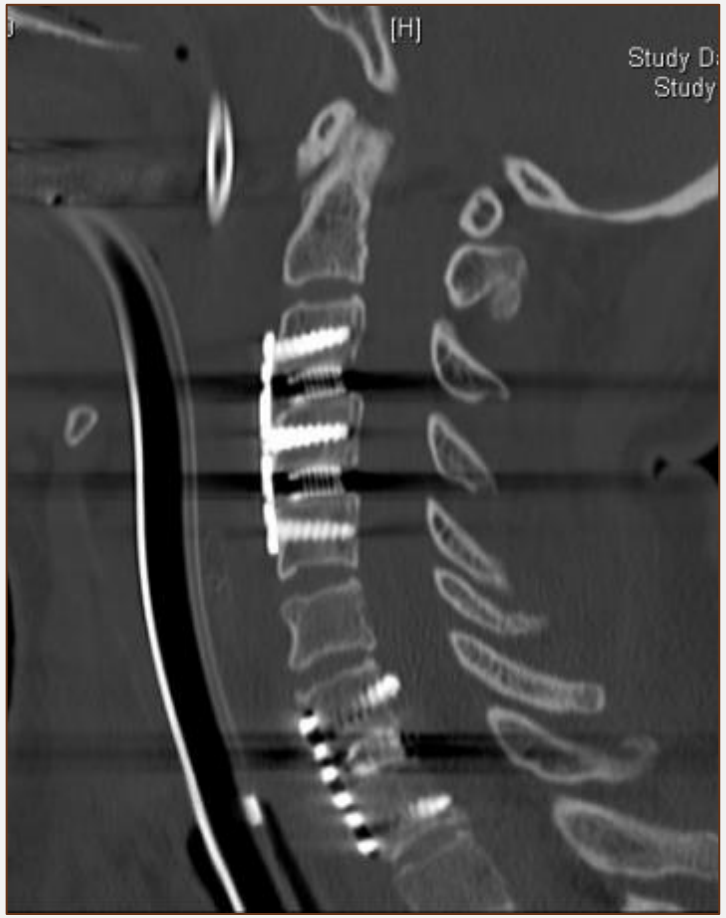
[H]
Study D
Study

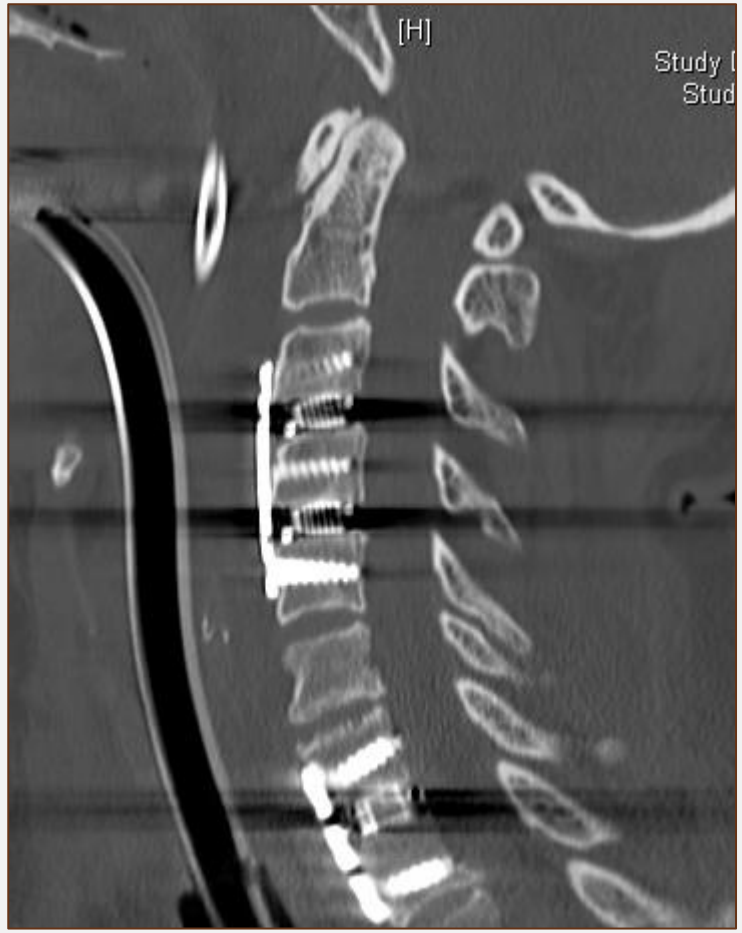
[H]
Study
Stud

38 ans chute en VTT

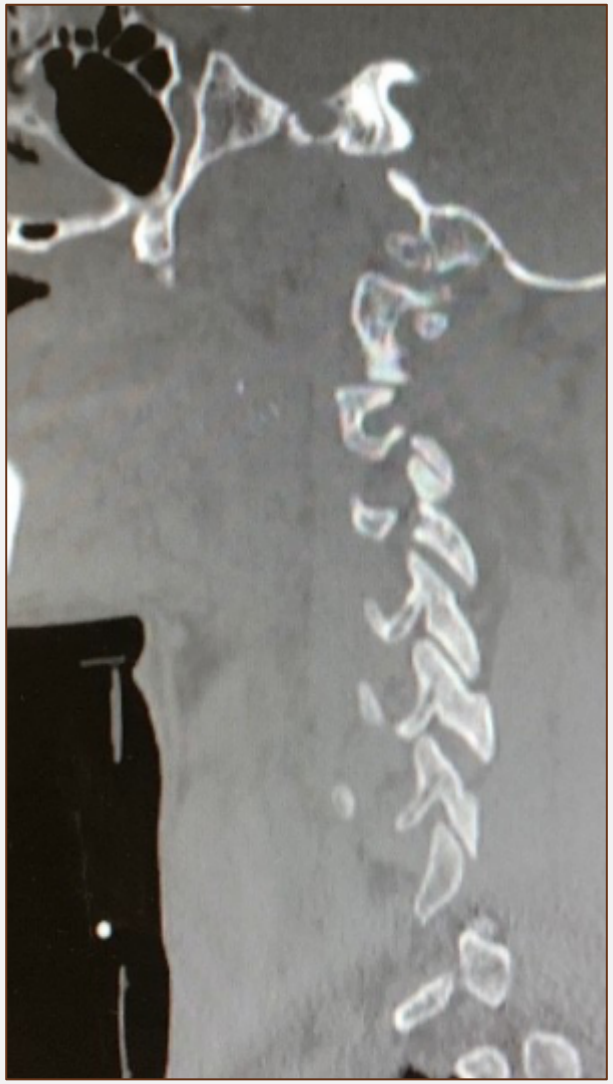

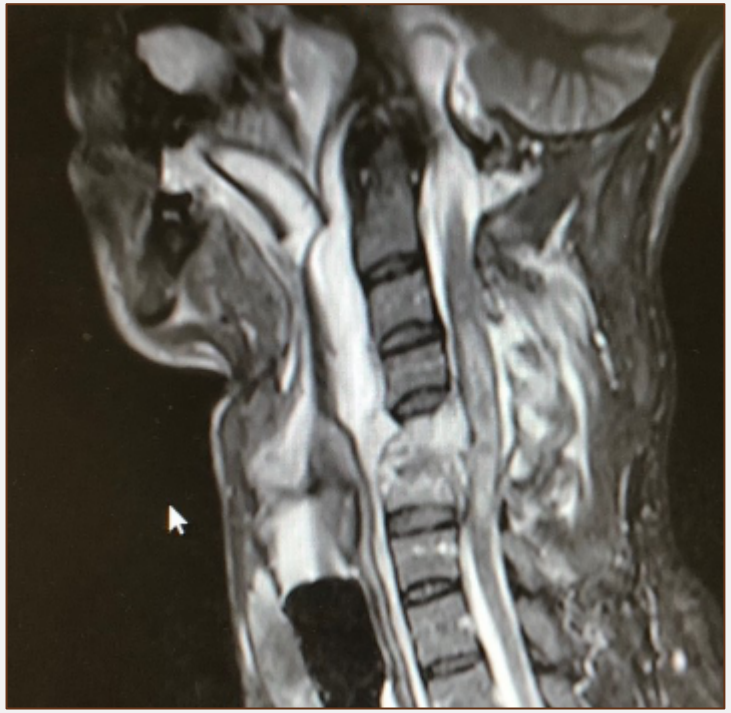

- Argenson : Tear-Drop A3
- Score SLIC : 4+2+2 = 8
- Aospine : Type C, F4, N4

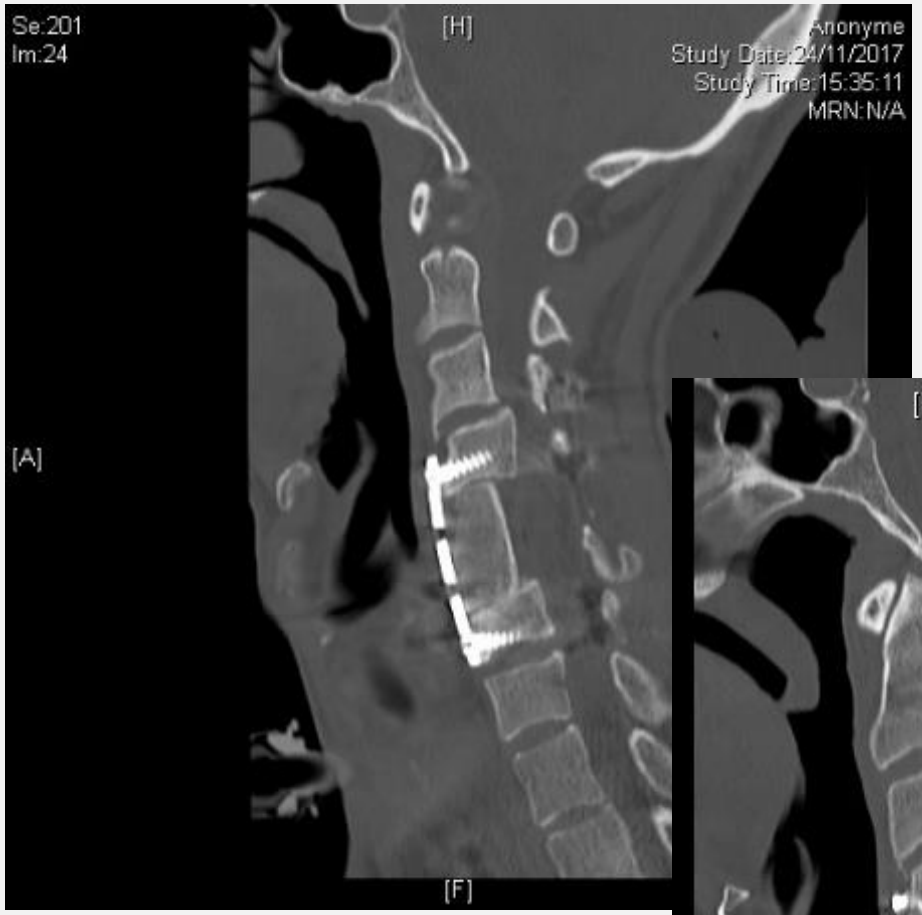
Se:201
Im:24
[H]
Anonyme
Study Date:24/11/2017
Study Time:15:35:11
MRN:N/A
[A]
[F]

[H]
[F]

[H]
[F]

[H]
Filter
/rot
[F]

84 ans chute déficit multi radiculaires C6/C7/C8

[HL]
Study Da
Study
[FR]

[HL]
Study Da
Study
[FR]

[HL]
Study Dat
Study T
[FR]

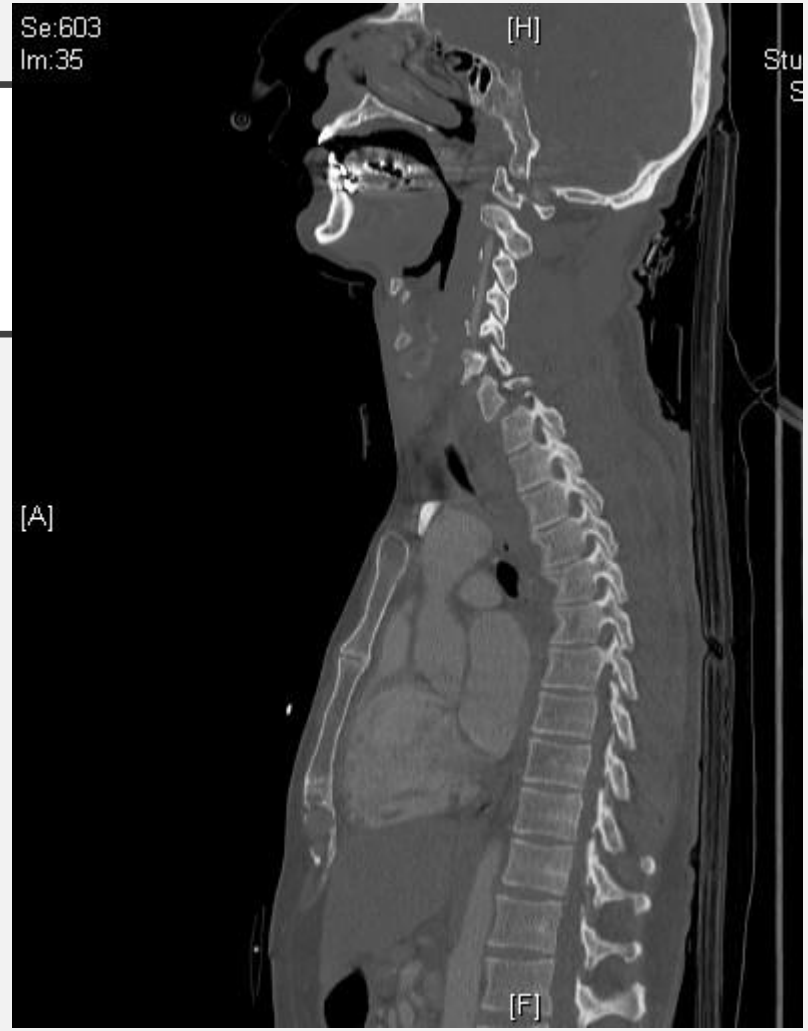

Homme 29 ans avp moto
Tétraplégique

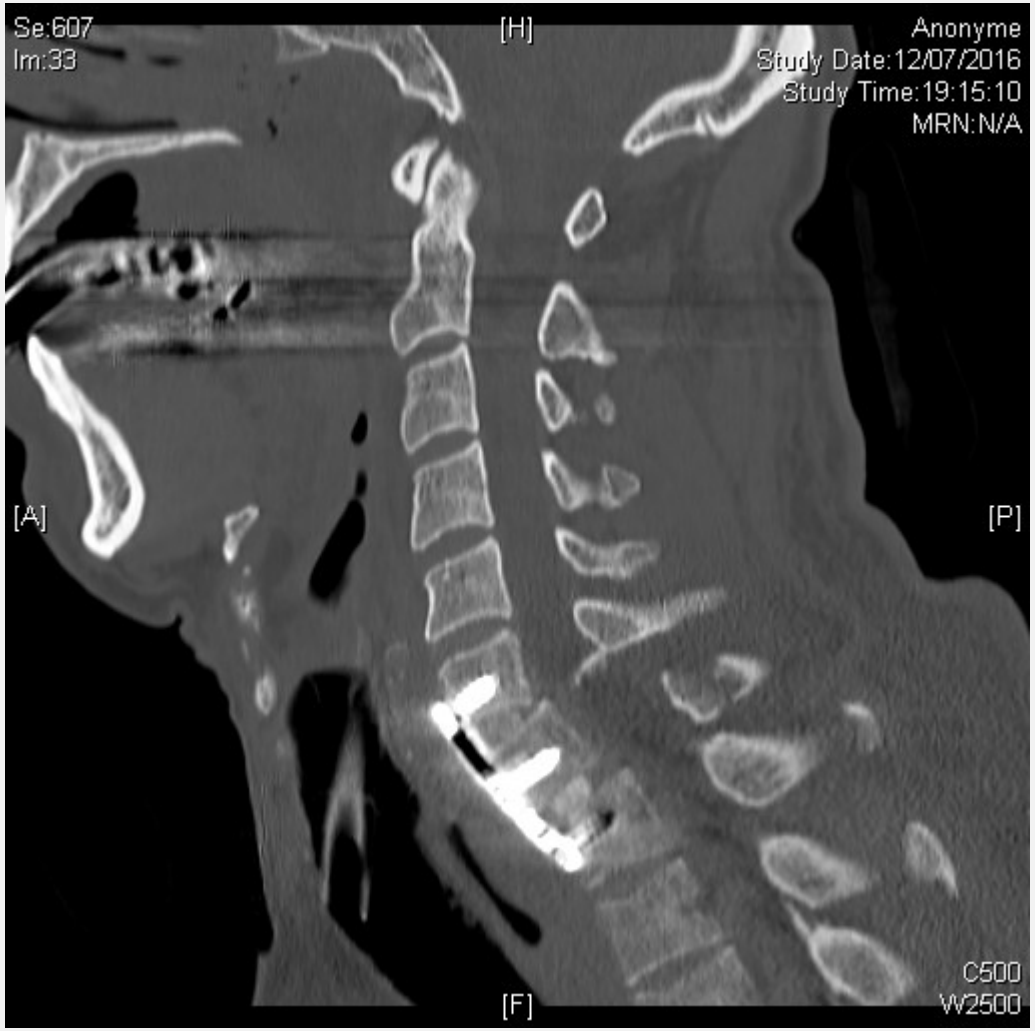
Se:607
Im:33
[H]
Anonyme
Study Date:12/07/2016
Study Time:19:15:10
MRN:N/A
[A]
[P]
[F]
C500
W2500

Se:607
Im:32
[H]
Anonyme
Study Date:12/07/2016
Study Time:19:15:10
MRN:N/A
[A]
[P]
[F]
C500
W2500

[H]
[F]

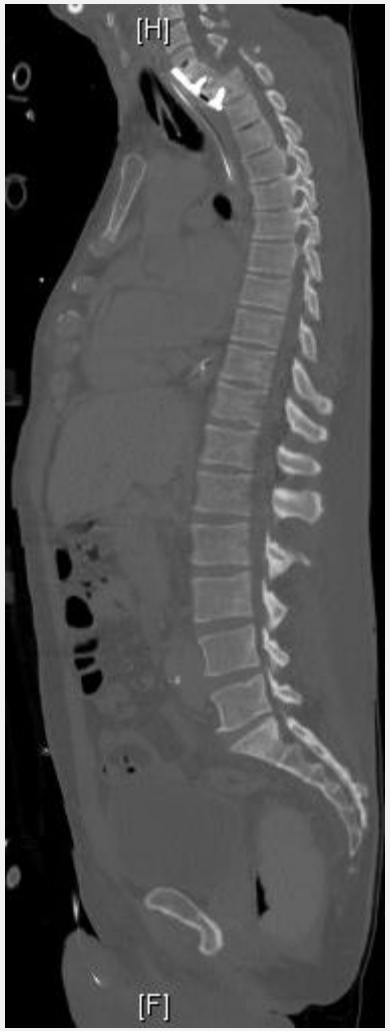
[H]
[F]

A
MF 1.73
TR 2590.0
TE 113.0

Trois temps chirurgicaux:

Devant: AMOS corporectomie

Derrière: Arthrectomie ostéosynthèse

Devant: Greffon plaque.

25 ans accident de travail impact occipital
Tétraplégique post traumatique.

[H]
[F]

[H]
[F]

[H]
[F]

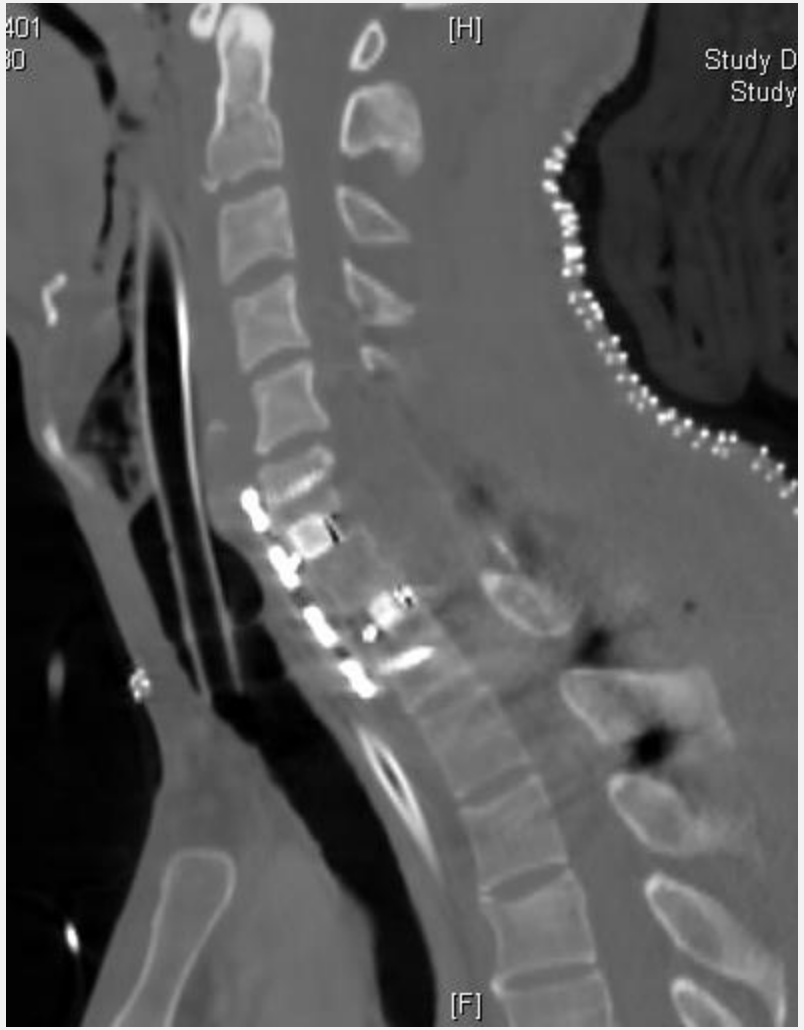
401
30
[H]
Study D
Study
[F]

Se:401
Im:22
[H]
Study D
Study
[A]
[F]

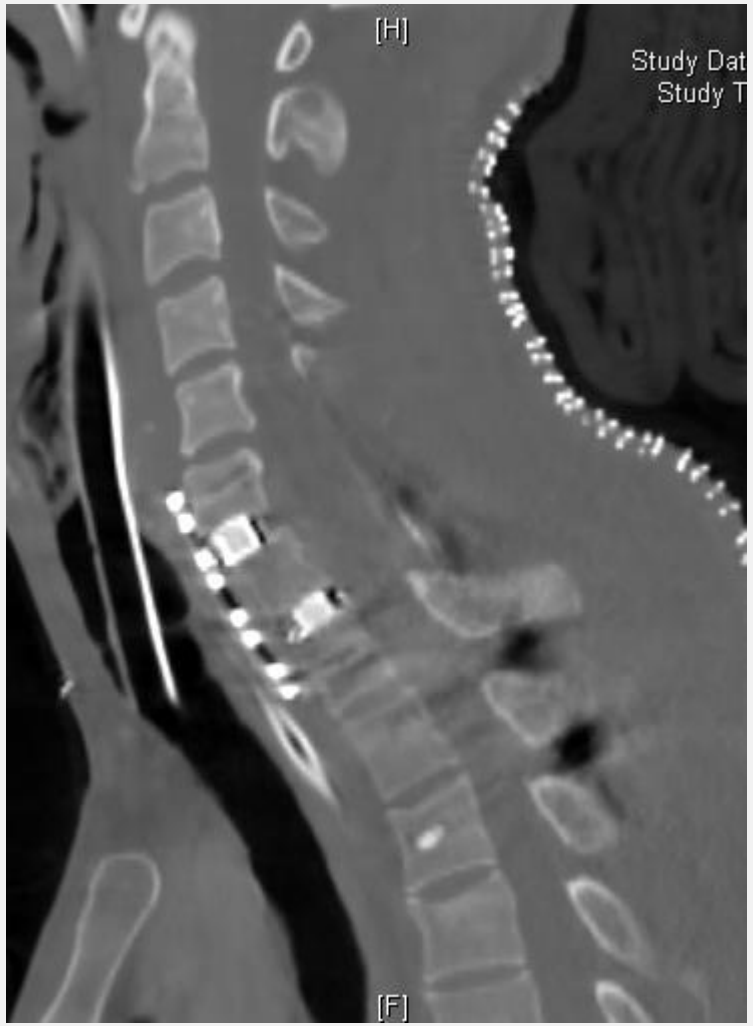
[H]
Study Dat
Study T
[F]

CONCLUSION

- Importance de l'IRM
- Etat disco-ligamentaire
- Nécessité classification simple et reproductible
- Standardisation de la prise en charge